



# Arthroscopic Assisted Reduction of a Salter-Harris Type III Fracture of the Distal Femur with Concomitant Anterior Cruciate Ligament Reconstruction: a Case Report

Andrew Gambone, MD  
Alexander Akoto, BA  
Todd Blumberg, MD  
Susan Nelson, MD, MPH  
Daniel Miller, MD  
Lawrence Wells, MD

## Abstract

Anterior Cruciate Ligament rupture in the presence of a Salter-Harris Type III fracture of the distal femur is an uncommon injury in the pediatric population. It can be caused by a combination of a valgus and rotational force applied to the knee. This injury most likely represents a sequence of events in which the distal femur fracture is preceded by rupture of the anterior cruciate ligament. Traditionally, these injuries have been addressed at separate operative settings, with fixation of the femur occurring on an acute basis and the ACL rupture being addressed later. However, this has the potential to prolong rehabilitation, result in chondral injury, and delay overall return to sports.<sup>2</sup> Here, we present a case of an arthroscopic assisted fixation of a Salter-Harris type III fracture of the distal femur along with concomitant ACL reconstruction.

## Introduction

ACL rupture in the presence of a distal femoral physeal fracture is rare, however the presence of physeal fracture does not exclude concomitant ligament injury.<sup>1</sup> The incidence of ACL tears has increased over the years in the pediatric population likely due to increased sports participation and the use of advanced imaging.<sup>2</sup> A better understanding of the ACL anatomy, the physis, and the natural history of ACL insufficient knees has changed the management of these injuries. The current treatment for ACL tears is arthroscopic assisted reconstruction.

Isolated distal femur fractures may be managed operatively or non-operatively depending on the degree of displacement.<sup>3</sup> Salter Harris type III/IV fractures of the distal femur are particularly difficult injuries to manage both in the short and long term; the extent of physeal involvement and intra-articular nature increases the risk for growth arrest and future degenerative joint changes.<sup>4</sup> Anatomic reduction of the joint surface is required. Typically, this is achieved through open reduction and internal fixation. We present an alternative visualization of the joint surface arthroscopically.

We report the case of a 14-year-old soccer player with an ACL rupture in the presence of a

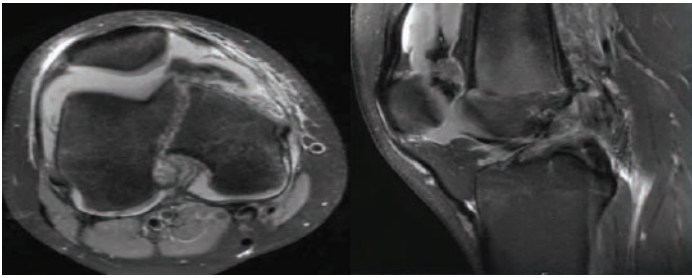
Salter-Harris type III fracture of the distal femur who was treated with arthroscopy assisted fracture reduction and ACL reconstruction during the same operative setting.

## Case Information

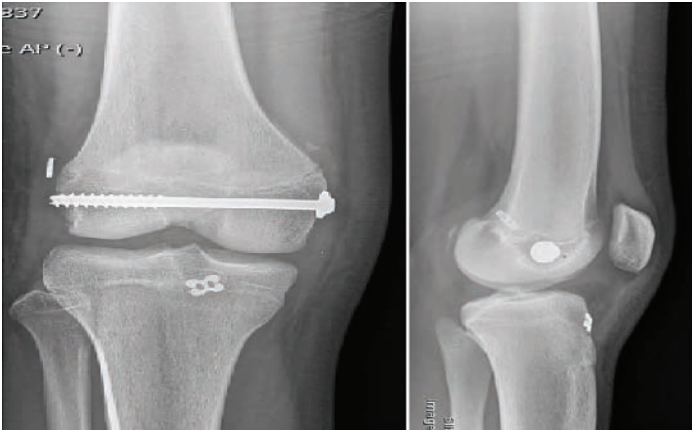
A 14-year-old female injured her right knee during a soccer game while attempting to make a shot on goal, colliding with the goaltender. The right knee was forced into valgus and internal rotation while her knee was extended and her foot planted. She presented immediately to the emergency department of an outside hospital with right knee pain and swelling. Anteroposterior, lateral, and oblique plain radiographs revealed widening of the medial distal femoral physis. An MRI was ordered to further evaluate the amount of displacement, and it confirmed a Salter-Harris type III fracture with minimal displacement and revealed a complete tear of the anterior cruciate ligament (Figure 1).

The patient was seen at our institution where operative and non-operative treatment options were discussed with the patient and her family. Given the patient's desire to return to athletics and start early range of motion, operative management of both the distal femur fracture and ACL tear during the same operative setting was chosen.

The patient was brought to the operating room placed in the supine position. Arthroscopic evaluation of the knee joint revealed a minimally displaced fracture of the medial femoral condyle extending into the intercondylar notch. A complete mid-substance of the ACL was visualized. The fracture was reduced closed, and reduction was confirmed under fluoroscopy as well as direct arthroscopic visualization of the joint surface. A 7.3 mm x 80 mm partially-threaded cannulated screw augmented with a washer was placed across the fracture site to obtain interfragmentary compression (Figure 2). Exam under anesthesia revealed that the fracture was stable. A guide pin was then placed in the epiphysis across the fracture site midline with the diaphysis to ensure screw placement did not violate the intercondylar notch and interfere with femoral tunnel placement for



**Figure 1.** MRI of the right knee demonstrates a minimally displaced fracture of the medial femoral condyle extending into the intercondylar notch as well as a complete tear of the ACL.



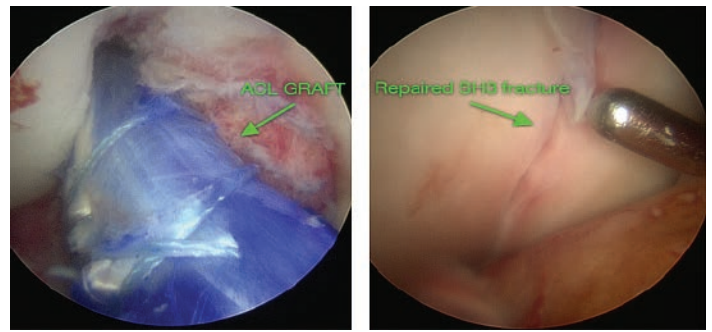
**Figure 2.** Intraoperative fluoroscopic images post percutaneous screw fixation and ACL reconstruction.

ACL reconstruction. The ACL was then reconstructed via an all inside technique utilizing a 6-strand semitendinosus and gracilis autograft (Figure 3).

The patient was placed in a hinged knee brace locked in 10 degrees of hyperextension. The brace was unlocked for range of motion exercises. The patient was brought back to the operating room at 7-weeks post-op for manipulation of her right knee under anesthesia for concerns of early arthrofibrosis. Afterwards, her post-operative course was uneventful and she regained full knee range of motion.

## Discussion

Distal femoral physeal fractures with concomitant ligamentous knee injuries present a challenging problem for both the patient and clinician. The physeal injury itself carries with it a risk of growth arrest which can lead to a limb length discrepancy and angular deformity.<sup>3,4</sup> Depending on the amount of growth remaining, this can be significant and result in the need for additional surgical procedures. Salter-Harris type III/IV fractures are of particular concern given their intra-articular nature and inherent instability. Open reduction and internal fixation is typically recommended to achieve a congruent joint. However, the extensive soft tissue dissection required for knee arthrotomy is associated with increased surgical morbidity such as bleeding, infection, arthrofibrosis, and further injury to the physis.<sup>3,5</sup> Even in the absence of



**Figure 3.** Arthroscopic images of ACL reconstruction with hamstring autograft and reduced Salter-Harris III fracture.

surgical complications, the expected scar formation can make future arthroscopic procedures much more challenging.

Besides the technical difficulties, staging the ACL reconstruction has the potential to negatively affect functional outcomes and quality of life. Closed reduction and casting is applicable only with a nondisplaced fracture or a stable fracture pattern and does not allow immediate range of motion. However, clinicians should have a low threshold for ordering advanced imaging such as CT or MRI to fully evaluate for any fracture displacement.<sup>6</sup> Open reduction and internal fixation with arthrotomy may result in higher morbidity and may also slow the return of full range of motion. Limited knee range of motion prior to ACL reconstruction has shown to adversely affect outcomes, compelling surgeons to postpone surgery until range of motion is improved.<sup>7</sup>

## Prior Reports and Relevant Literature

Previous reports of Salter-Harris type III femur fractures with concomitant ACL injuries have detailed a staged strategy of surgical management.<sup>1,8</sup> In these cases, the distal femur fractures were addressed via open reduction and internal fixation. Removal of the fixation hardware and ACL reconstruction were then performed once the patient had regained adequate range of motion in the knee, 2-3 months later.<sup>9</sup> Importantly, the multiple operations involved in this staged strategy also provide multiple opportunities for perioperative complications contrasted with the single operation detailed here. Furthermore, the removal of fixation hardware during ACL reconstruction raises the question of increased risk for refracture of the distal femur.<sup>9,10</sup>

## Conclusions

Arthroscopic assisted reduction and percutaneous fixation of intraarticular distal femur fractures minimizes soft tissue dissection, provides confirmation of anatomic reduction under direct visualization, allows for early range of motion, and obviates the need for an additional planned procedure when done in conjunction with ACL reconstruction.

The case presented in this study is, to our knowledge, the first documented arthroscopic assisted reduction of Salter-Harris type III fracture of the distal femur in conjunction with reconstruction of the anterior cruciate ligament during the same operative setting in the English literature.

## References

- Bertin KC, Goble EM.** Ligament injuries associated with physeal fractures about the knee. *Clin Orthop* 177: 188–195, 1983
- Kocher M, Garg, S, Micheli L.** Physeal sparing reconstruction of the anterior cruciate ligament in skeletally immature prepubescent children and adolescents. Surgical technique. *J Bone Joint Surg Am.* 2006 Sep;88 Suppl 1 Pt 2:283-93.
- Edmunds I, Nade S.** Injuries of the distal femoral growth plate and epiphysis: should open reduction be performed? *Aust N Z J Surg.* 1993;63:195–199
- Graham JM, Gross RH.** Distal Femoral Physeal Problem Fractures. *Clinical Orthopaedics and Related Research*, 1990 (255); 51-53
- Gittings D, Hesketh, P, Mehta S.** Arthroscopic lysis of adhesions improves knee range of motion after fixation of intra-articular fractures about the knee. *Arch Orthop Trauma Surg.* 2016 Dec;136(12):1631-1635. Epub 2016 Aug 30.
- Lippert, W, Owens, R, Wall, Eric.** Salter-Harris Type III Fractures of the Distal Femur: Plain Radiographs can be Deceptive. *J Pediatr Orthop.* 2010 Sep;30(6):598-605
- Wright R, Haas M, et al.** Anterior Cruciate Ligament Reconstruction Rehabilitation: MOON Guidelines. *sports Health.* 2015 May;7(3):239-43
- Herrera MF, Roth NS.** Salter-Harris Type III Fracture of the Medial Femoral Condyle Associated with an Anterior Cruciate Ligament Tear. *American Journal of Sports Medicine.* 2003 31(5): 783-786
- Brone R, Wroble A.** Salter-Harris type III fracture of the medial femoral condyle associated with an anterior cruciate ligament tear—Report of three cases and review of the literature. *American Journal of Sports Medicine.* 1998 July; 26, (4), p. 581—586
- Han, Y, Sarder Z, Martineau et al.** Peri-anterior cruciate ligament reconstruction femur fracture: a biomechanical analysis of the femoral tunnel as a stress riser. *Knee Surg Sports Traumatol Arthrosc.* 2011 Dec;19 Suppl 1:S77-85