

# Interposition of a Cell-seeded Slow-Degrading Membrane Generates a Stable Osteochondritis Dissecans-Like Lesion in a Large Animal Model

James Friedman, MD<sup>1,2</sup>  
 Mackenzie Sennett, BS<sup>1,2</sup>  
 Marcelo Bonadio, MD<sup>1,3</sup>  
 Kerry Orji, BS<sup>1</sup>  
 Blair Ashley, MD<sup>1,2</sup>  
 Robert Mauck, PhD<sup>1,2</sup>  
 James Carey, MD<sup>1,2</sup>

<sup>1</sup>University of Pennsylvania  
 Philadelphia, PA, USA

<sup>2</sup>Philadelphia VA Medical Center  
 Philadelphia, PA, USA

<sup>3</sup>University of São Paulo  
 São Paulo Brazil

## Introduction

Osteochondritis dissecans (OCD) is a rare but damaging disease that commonly affects skeletally immature individuals and is defined as the separation of an osteochondral fragment (progeny) from surrounding bone (parent bone). There is great interest in identifying the most effective treatment for this disease. However, the rarity and young patient population makes study in humans difficult. A recent pilot study by our group reported successful creation of OCD-like lesions in a porcine model at a two-week time point with the interposition of either collagen (CM) or fenestrated poly( $\epsilon$ -caprolactone) (fenPCL) membranes between a surgically created progeny fragment and parent bone<sup>1</sup>. The purpose of this study was to assess the durability of this non-union between the osteochondral fragment and surrounding subchondral bone at 5 and 10 weeks, as well as the impact of fibrous cell delivery on this process.

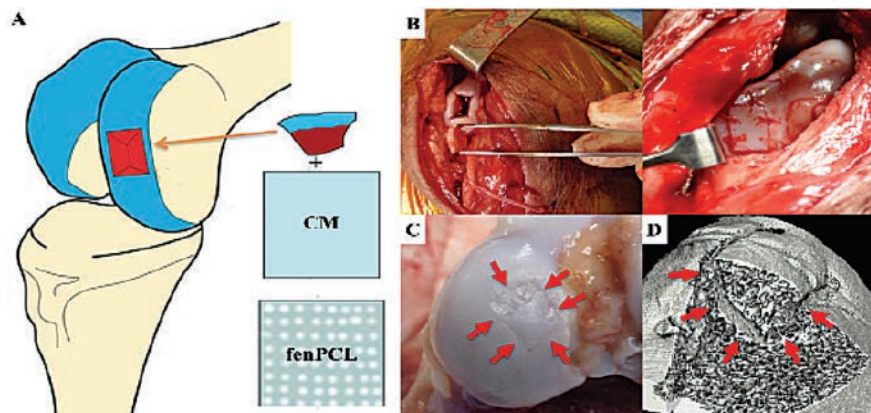
## Methods

All animal procedures were approved by the Institutional Animal Care and Use Committee (IACUC) in accordance with NIH policy. Osteochondral fragments (progeny) were created bilaterally in the medial femoral condyles (parent bone) of 16 juvenile male Yucatan mini-pigs. Membranes were placed into the defect and the progeny fragment was secured with transchondral sutures (Figure 1). Membranes included CM (5wk: n = 5; 10wk: n = 3), fenPCL (5wk: n = 5; 10wk: n = 3), tenocyte-

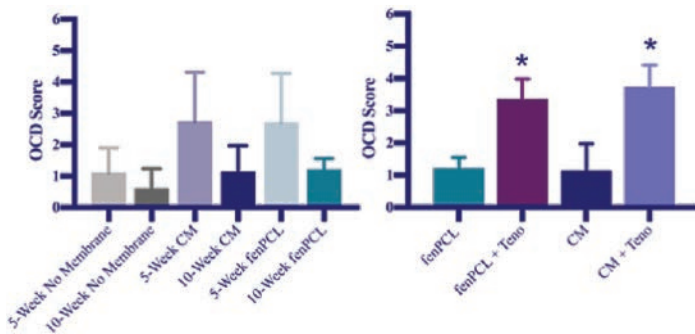
seeded CM (10wk: n = 2), and tenocyte-seeded fenPCL (10wk: n = 3). Prior to scaffold seeding, allogeneic porcine tenocytes were isolated from excised patellar tendon. Diced tendon fragments were placed in high glucose DMEM supplemented with 10% FBS and 1% Antibiotic-Antimycotic for 1 week before removal of tendon tissue. Isolated tenocytes were expanded through passage 2 before seeding on fenPCL or CM at a density of  $1.6 \times 10^5$  cells/cm<sup>2</sup>. Tenocyte-seeded membranes were cultured in chemically defined media with 10 ng/ml TGF- $\beta$ 3 for two weeks before implantation. Animals were sacrificed at 5 or 10 weeks after defect creation. Gross inspection, X-ray, micro-computed tomography ( $\mu$ CT), and histology were used to analyze each defect. Experimental groups were compared against control defects with no interposed membrane (5wk: n = 3; 10wk: n = 2). Three blinded scorers assessed the degree of union between the progeny fragment and parent bone on randomly selected  $\mu$ CT slices from all defects. Statistics were performed using one-way ANOVA with Tukey's post-hoc.

## Results

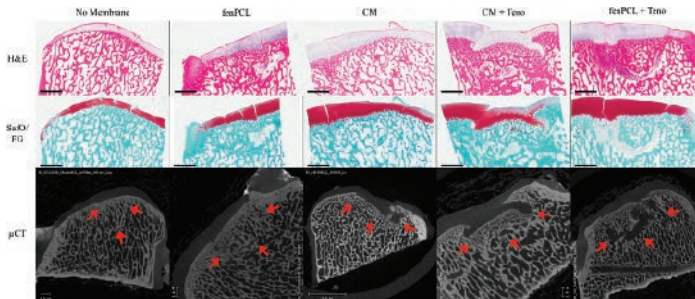
Grossly, all defects were visible at the time of euthanasia with a clear demarcation between progeny fragment and parent bone cartilage. Blinded  $\mu$ CT scoring showed no significant difference in bone healing between acellular groups at 5 and 10 weeks. CM and fenPCL showed a trend towards higher levels of non-union at 5 weeks, but had mostly healed by



**Figure 1.** OCD-like lesion creation. **(A)** Schematic showing defect localization on medial femoral condyle as well as collagen and fenestrated PCL membranes. **(B)** Intraoperative views of progeny fragment removal and replacement with transchondral sutures after membrane placement. **(C)** Post-mortem gross view of OCD-like lesion **(D)** Cut-away view of  $\mu$ CT volume-rendering showing perilesional border within the condyle.



**Figure 2.** Blinded scoring of  $\mu$ CT images (mean +sd). Three random  $\mu$ CT slices per defect were assigned a score of 0 (complete bone healing) – 6 (complete non-union). No significant differences were found between acellular groups at 5 or 10 weeks (left), but seeded membranes resulted in significantly less healing at 10 weeks (right). (\* =  $p < 0.05$ ).



**Figure 3.** Hematoxylin & Eosin (H&E) and Safranin O/Fast Green (Saf O/FG) staining and  $\mu$ CT images of sections from all groups at 10-weeks post-surgery. Scale bar = 2 mm.

10 weeks. Conversely, tenocyte-seeding of membranes significantly increased the degree of non-union at 10 weeks (Figure 2). Control groups showed nearly complete healing by 10 weeks (Figure 3). Histological analysis confirmed the  $\mu$ CT findings, with all acellular groups showing substantial bone healing and incomplete cartilage healing at 10 weeks (Figure 3). Tenocyte-seeded CM defects showed subsidence of the progeny fragment into the surrounding parent bone. In tenocyte-seeded fenPCL defects, a hypercellular, fibrous border was present around the edge of the progeny fragment.

## Discussion

Tenocyte-seeded collagen and fenPCL membranes generated a higher degree of non-union at 10 weeks than acellular membranes. The addition of tenocytes may have resulted in the continuous generation of fibrous matrix that eventually replaced the degradable membranes, allowing for a more persistent fibrous non-union. While CM+teno and fenPCL+teno defects showed similar degrees of non-union, CM+teno progeny fragments subsided into the parent bone whereas fenPCL+teno progeny fragments remained flush with surrounding bone and cartilage. Clinically, OCD lesions are typically flush or slightly proud. The ability of fenPCL+teno membranes to generate non-union while keeping the progeny fragment flush at 10 weeks make it the best candidate for a clinically-relevant animal model of OCD. This animal model will provide a platform to evaluate interventional therapies in future studies.

## Significance

This study demonstrates that a tenocyte-seeded fenPCL membrane is capable of generating a stable stage III OCD-like lesion in a Yucatan mini-pig. This animal model will provide a platform in which to evaluate interventional therapies for the treatment of OCD in future studies.

## Acknowledgements

Funded by The University of Pennsylvania Department of Orthopaedic Surgery, Sports Medicine Division and the Penn Center for Musculoskeletal Disorders.

## References

1. Pfeifer CG, Kinsella SD, Milby AH, Fisher MB, Belkin NS, Mauck RL, Carey JL. Development of a large animal model of osteochondritis dissecans of the knee: a pilot study. *Orthopaedic Journal of Sports Medicine*. 2015 Feb 16;3(2):2325967115570019.