



Inflammatory Cytokine and Catabolic Enzyme Expression in a Goat Model of Intervertebral Disc Degeneration

Chenghao Zhang^{1,2}
Thomas P. Schaer¹
Sarah E. Gullbrand^{1,2}
Zhirui Jiang^{1,2}
Yian Khai Lau^{1,2}
Dawn M. Elliott³
George R. Dodge^{1,2}
Robert L. Mauck^{1,2}
Neil R. Malhotra¹
Lachlan J. Smith^{1,2}

¹University of Pennsylvania, Philadelphia, PA

²Corporal Michael J. Crescenz Philadelphia VA Medical Center, Philadelphia, PA

³University of Delaware, Newark, DE

Introduction:

Intervertebral disc degeneration is implicated as a leading cause of low back pain. Persistent, localized inflammation within the disc nucleus pulposus (NP) and annulus fibrosus (AF) is considered to be a key mediator of disc degeneration, and is associated with downstream catabolic enzyme activity and extracellular matrix destruction. Disc inflammation is characterized by expression of cytokines including IL-1 β , IL-6 and TNF- α , amongst others, with expression levels positively correlating with severity of degeneration¹. There is currently a lack of validated preclinical animal models of disc degeneration that recapitulate clinically-relevant, persistent local disc inflammation. We recently described a goat model of disc degeneration in which increasing doses of chondroitinase ABC (ChABC) were used to reproducibly induce a spectrum of structural, biomechanical and histological degenerative changes.² The objective of this study was to evaluate and extend the clinical-relevance of this model by establishing whether these degenerative changes are associated with tissue-level expression of inflammatory cytokines and downstream catabolic enzymes.

Methods

With IACUC approval, 9 adult male goats underwent surgery to induce degeneration of the lumbar intervertebral discs. Using an open, lateral, retroperitoneal transposoatic approach, L1-2, L2-3 and L3-4 lumbar discs were randomized to receive either subtotal mechanical nucleotomy (n = 4) or injection of 200 μ L of 0.1U, 1U or 5U ChABC via a 22G spinal needle (n = 4 per dose). The L4-L5 disc (n = 4) received a sham saline injection, and the T13-L1 and L5-L6 discs served as intact controls. Animals were euthanized 12 weeks after surgery, and lumbar spines harvested. Discs were imaged using a 3T MRI scanner, and NPT2 and T1 ρ relaxation times were determined.² Discs (with bony endplates intact) were then isolated, fixed in formalin, decalcified, and processed for paraffin histology. Mid-sagittal sections were double stained with either Alcian blue (glycosaminoglycans) and picosirius red (collagen), or hematoxylin and eosin. Severity of degeneration was established via semi-quantitative histological grading.²

Immunohistochemistry was performed to investigate expression of inflammatory cytokines (IL-1 β , IL-6, TNF- α) and catabolic enzymes (MMP-1, MMP-13 and ADAMTS4) in the NP and AF. Sections were counterstained with hematoxylin and imaged using bright field microscopy. Expression levels were quantified by determining the percentage of positive vs. total cells in the NP and AF. Differences in expression between groups were established using Kruskal-Wallis tests with post-hoc Dunn's tests ($p < 0.05$). Spearman rank correlations between degenerative condition (histology and MRI scores) and expression levels of cytokines and enzymes were determined.

Results

Positive cytokine and enzyme staining was found to various degrees in the NP and AF of most discs (examples, Fig 1). Multiple comparisons tests revealed significant effects of intervention type on expression levels of inflammatory cytokines and catabolic enzymes in both the NP (Fig 2) and AF (not shown). For cytokines, TNF- α expression was significantly elevated in 1U ChABC discs compared to controls, while IL-1 β and IL-6 expression were significantly elevated in both the NP and AF of 5U ChABC discs. For enzymes, MMP-13 was significantly elevated in the NPs of 0.1U ChABC discs, while ADAMTS-4 was significantly elevated in the NP and AF of both 0.1 and 5U ChABC discs compared to controls. In general, both cytokine and enzyme expression levels were positively correlated with histological grade, and negatively correlated with MRIT2 (Fig 3) and T1 ρ times.

Discussion

Localized inflammation is a defining feature of human disc degeneration and is a key mediator of tissue breakdown and painful innervation. Anti-inflammatory therapies such as catabolic cytokine inhibitors^{3,4a} a condition strongly implicated as a cause of lower back pain. The objective of this study was to investigate the therapeutic potential of poly(lactic-co-glycolic acid) have the potential to slow the degenerative cascade and provide a microenvironment more conducive to stem cell-based disc regeneration; however, the absence of a preclinical animal model that effectively recapitulates inflammation

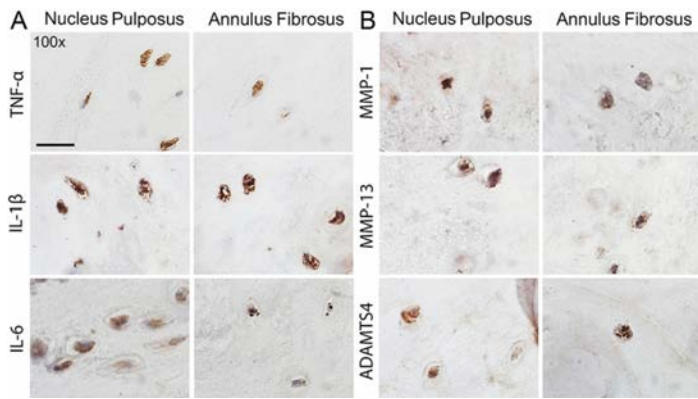


Figure 1. Immunostaining of **A.** Cytokines and **B.** Enzymes in the NP and AF of degenerate (1U ChABC-treated) goat discs. Scale = 20μm.

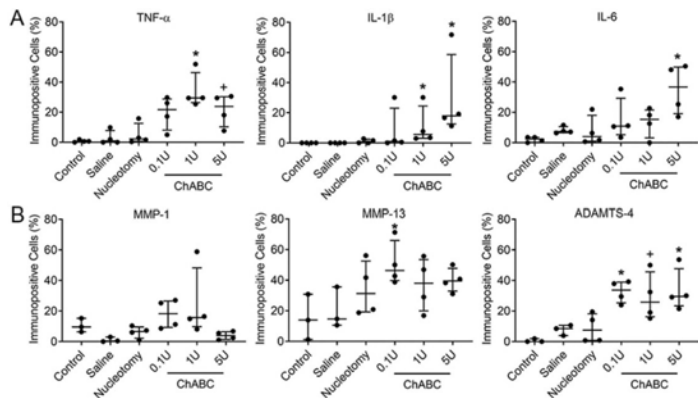


Figure 2. Effects of different surgical interventions on expression levels of **A.** Cytokines and **B.** Enzymes in the NP. N = 4; *p < 0.05 and +p < 0.1 vs. control.

represents an impediment to effective translation of such therapies. In this study, we provide evidence that an established goat model of disc degeneration is characterized by elevated expression of clinically-relevant inflammatory cytokines and downstream catabolic enzymes. This model exhibits significantly elevated expression in moderately to severely degenerate discs treated with ChABC, suggesting that these discs may provide the most suitable models for evaluating anti-inflammatory therapies. We also show that non-invasive, quantitative MRI is a reliable predictor of the inflammatory state of the disc. We are currently applying this model towards our goal of evaluating anti-inflammatory and cell-based therapies for disc regeneration.

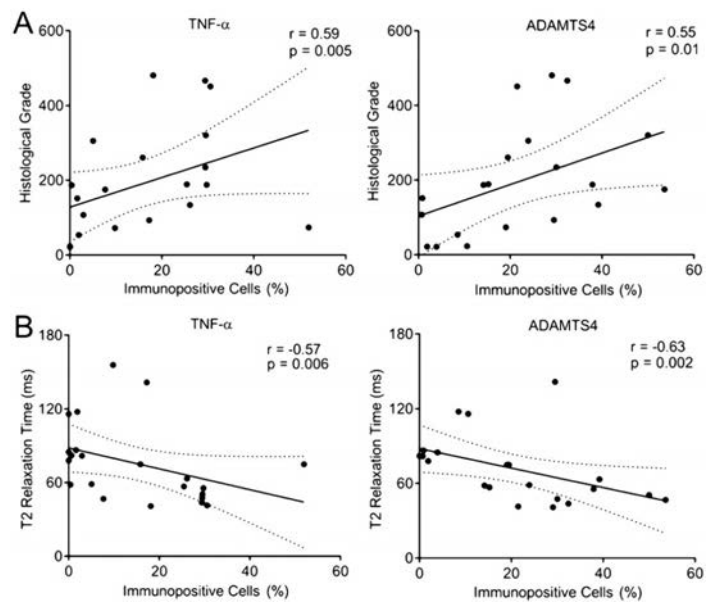


Figure 3. Correlations between NP cytokine and enzyme expression levels and **A.** Overall histological grade; and **B.** NP MRI T2 times.

Conclusion

Anti-inflammatory and cell-based therapies represent promising treatment strategies for painful disc degeneration. The animal model described here provides a platform for preclinical evaluation of such therapies and progressing them towards clinical use.

References:

1. Risbud, M. V & Shapiro, I. M. Role of cytokines in intervertebral disc degeneration: pain and disc content. *Nat. Rev. Rheumatol* 2014; 10, 44–56
2. Gullbrand, S. E., Malhotra, N. R., Schaefer, T. P., et al. A large animal model that recapitulates the spectrum of human intervertebral disc degeneration. *Osteoarthritis Cartil*. 2017; 25, 146–156
3. Gorth, D. J., Mauck, R. L., Chiaro, J. A., et al. IL-1ra delivered from poly(lactic-co-glycolic acid) microspheres attenuates IL-1beta-mediated degradation of nucleus pulposus in vitro. *Arthritis Res. Ther*. 2012; 14, R179
4. Sainoh, T., Orita, S., Miyagi, M., et al. Single Intradiscal Administration of the Tumor Necrosis Factor-Alpha Inhibitor, Etanercept, for Patients with Discogenic Low Back Pain. *Pain Med*. 2016; 17, 40–45