



Arthroplasty Tips & Tricks: Manual Fixed-Bearing Medial Unicompartmental Arthroplasty

Yehuda E. Kerbel, MD¹

Rahul Singh, MBBS²

Pedro N. Giglio, MD³

Neil P. Sheth, MD¹

¹Department of Orthopaedic Surgery, The University of Pennsylvania

²Department of Orthopaedic Surgery, Wockhardt Hospital, Mumbai, India

³Department of Orthopaedic Surgery, University of Sao Paulo

Introduction

Patients presenting with isolated single compartment degenerative joint disease may be considered for unicompartmental arthroplasty (UKA) after having exhausted conservative treatment. UKA offers the advantages of less invasive surgical exposure, preservation of bone stock, retention of cruciate ligaments, and easier post-operative recovery.¹ Previous studies demonstrate improved patient satisfaction following UKA as compared to total knee arthroplasty (TKA), with better range of motion at discharge, shorter hospital stay, improved functional scores, and equivalent survivorship.^{2,3}

As implant design and minimally invasive surgical techniques have improved over the last few decades, there has been increased interest in UKA and expansion of patient indications.⁴ In addition, recent technological advances have introduced the robotic-assisted UKA, which has been shown to lead to improved component positioning and comparable short-term survivorship to manual UKA.⁵⁻⁷

Despite the early promise of robotic-assisted UKA, most institutions do not readily possess this technology. In addition, intra-operative technical difficulties with the robot will require the procedure to be performed manually. Thus, it is critical for arthroplasty surgeons to still have the ability to perform the procedure without robotic assistance. Relatively little has been published in the primary literature describing the technical steps of the procedure.⁸ In this review, we present a systematic method for performing a manual fixed-bearing UKA in the appropriately selected patient with isolated medial compartment arthritis.

Indications

The current accepted indications for performing a UKA are⁹:

- Isolated single compartment arthritis
- Absence of inflammatory arthritis
- Varus or Valgus deformity < 10 degrees (a correctable deformity)
- Pre-operative range of motion > 90 degrees
- Flexion contracture of < 10 degrees

Historically, patient-specific contraindications included weight over 180 pounds, age greater than 60 or anterior cruciate ligament

incompetence.⁹ However, more recent studies demonstrate that even patients that don't fit the "ideal" criteria may have favorable clinical outcomes following UKA.¹⁰

Surgical Technique

Positioning

The patient is placed in a supine position with a bump under the ipsilateral hip, a tourniquet around the ipsilateral thigh and an Alvarado knee positioner at the level of the medial malleolus. Standard TKA prepping and draping is then performed. The incision is marked out just medial to the patella, starting from the proximal pole of the patella to a point 5cm distal and lateral. The limb is exsanguinated, and the tourniquet inflated to 100 mmHg above the starting systolic blood pressure.

Exposure

Once the tourniquet is inflated, the incision is made with a 10-blade through the skin and dermis and a Weitlaner retractor is placed in position. Dissection scissors are then used to continue down to the level of the medial retinaculum and extensor mechanism. Two knee joint retractors are used to expose the vastus medial obliquus (VMO). A fresh 10-blade is used to perform a mini-midvastus arthrotomy, and a retractor is placed deep to the VMO after delineating the space between the VMO and deep synovium using scissors. Dissecting scissors are used to remove the synovium medially and a single prong retractor is placed around the medial femoral condyle (MFC).

The medial meniscus is next excised using a bovie, beginning at its tibial attachment and working radially to release the anterior horn. Once the release reaches the anteromedial corner of the tibia, a single prong retractor is placed medially around the tibial plateau and a small medial collateral ligament (MCL) release is performed around the medial plateau to the posteromedial corner about 3-5mm from the joint line. A double prong retractor should then slide around the posteromedial tibial plateau easily in place of the single prong retractor which is now moved to the lateral aspect of the MFC in the intercondylar notch. At this point, the surgeon should have a clear view of the medial tibial plateau and the MFC. A small portion of the

infrapatellar fat pad can be resected in order to visualize the lateral aspect of the medial femoral condyle, which will guide the sagittal tibial resection.

Tibial Cut

The tibial resection guide is placed, and all its articulations are unlocked. The resection depth is set first using an angel wing, typically just below the anteromedial tibial osteophyte. Otherwise, a stylus can be used to measure a 2-3mm resection depth. Next, the varus/valgus portion of the jig is adjusted, with the typical position set at 2-3 clicks medially to ensure a neutral cut with regards to the tibial mechanical axis. Lastly, the tibial slope is set based on the preoperative X-rays, with the goal of restoring the native slope. The guide has 5 degrees of slope built in, which must be taken into account.

All articulations are then locked, and a single pin is placed into the tibia to secure the position. The tibial plateau is cut with an oscillating saw and the pin and cutting jig are removed. A single-sided reciprocal saw is then used to perform the sagittal tibial cut (Figure 1). The lateral aspect of the MFC is used as a guide for the mediolateral position of the cut. The cut is performed with a slight amount of external rotation to ensure that it is adjacent to the anterior cruciate ligament (ACL) footprint on the tibia. It is imperative to push the blade posteriorly along the intercondylar notch and perform the cut with an even distribution of force, without rocking the blade anteriorly and posteriorly. This avoids creating a stress riser on the tibial plateau. A 1-inch osteotome and Kocher clamp are used to remove the cut portion of the plateau (Figures 2 and 3); this part of the case can be performed in extension if the piece is difficult to remove.

Distal Femoral Cut

The leg is moved into extension and the 10 mm distal femur cutting guide is placed, followed by assembly of the

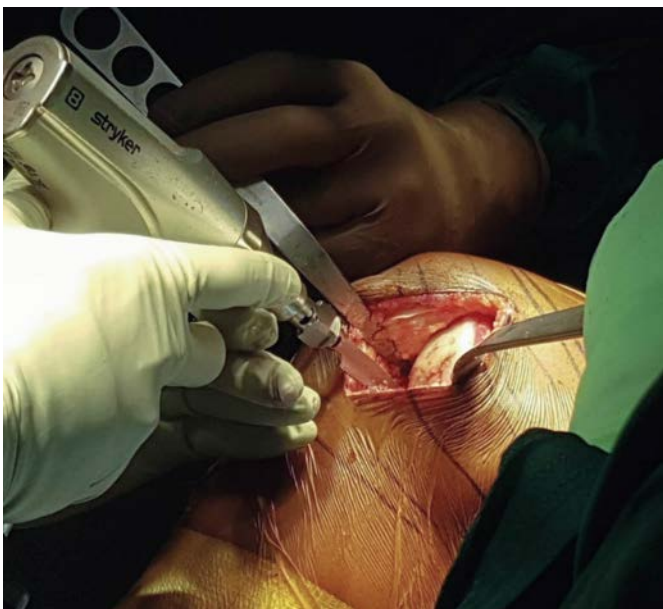


Figure 1. The second limb of the tibial cut.

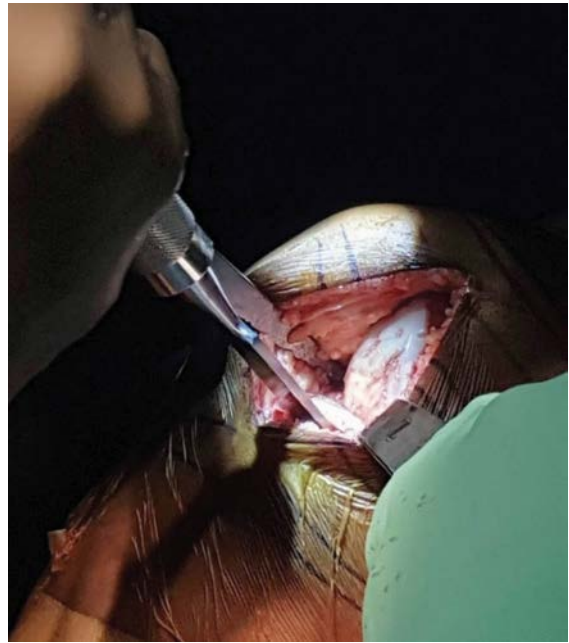

Figure 2. Removing the cut portion of the tibial plateau.

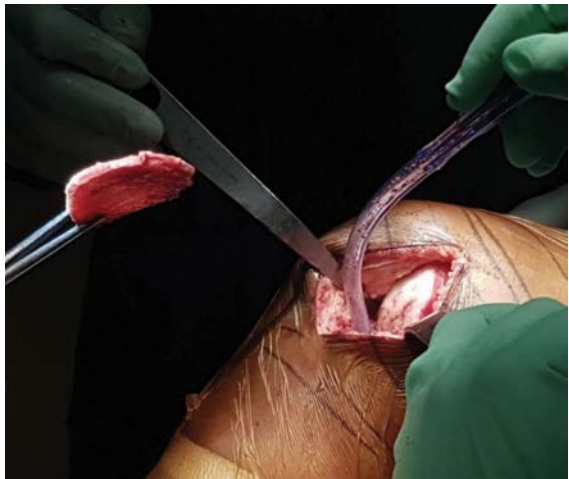

Figure 3. The removed portion of the tibial plateau.

alignment rod used to assess varus/valgus (Figure 4). The tibial resection surface should be parallel to the tibial mechanical axis to prevent valgus angulation. A slight varus tibial resection surface is acceptable. If the alignment is off at this point, the tibial resection should be fine-tuned as needed. If the alignment is appropriate, then the extra-medullary distal femoral cutting guide can be secured in place (Figure 5) and the distal femoral cut made (Figure 6) using a regular saw blade (Figure 7). This resection can be difficult as the cutting slot has minimal tolerance.

Assessment of the Flexion and Extension Gaps

Once both resections have been performed, the thick side of the 8 mm and 10 mm spacer guides are used to assess the extension gap. The 8mm spacer should go in easily with approximately 2 mm of laxity with a valgus stress, and the 10mm spacer should go in with no valgus laxity while

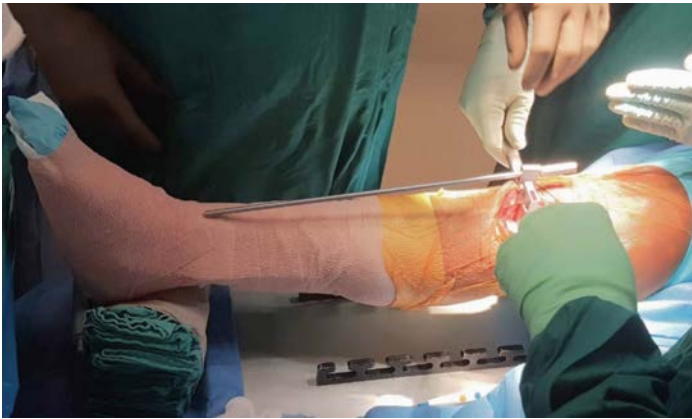


Figure 4. The alignment rod is used to assess varus/valgus.

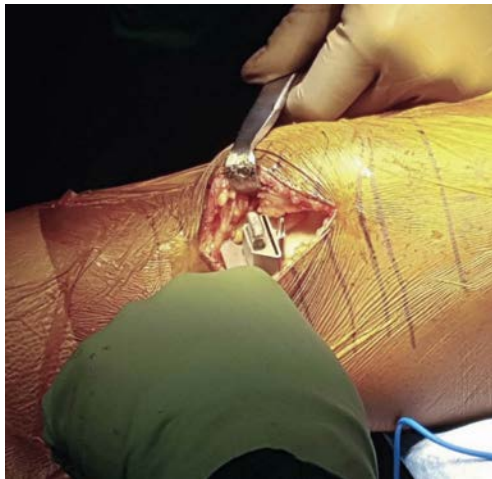

Figure 5. The femoral jig is pinned into place.

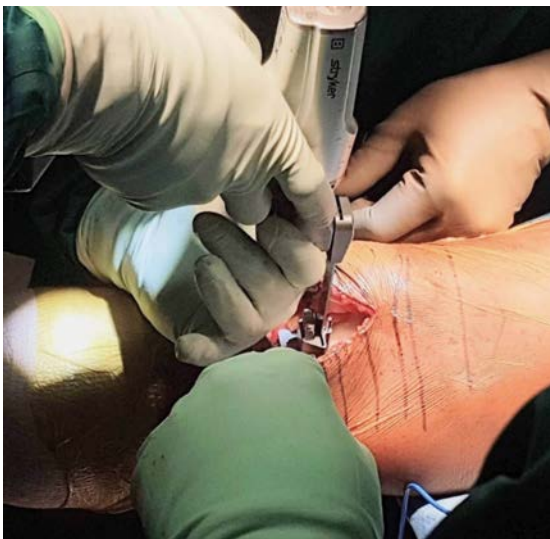

Figure 6. The femoral cut is made through the jig.

achieving full extension. The goal of the extension gap is to have 2 mm of laxity with an 8 mm polyethylene insert.

If the extension gap is adequate, the knee is then flexed, and the flexion gaps are similarly assessed with the thin portion of the 8 mm, 10 mm and 12 mm plastic spacer guides (Figure 8).

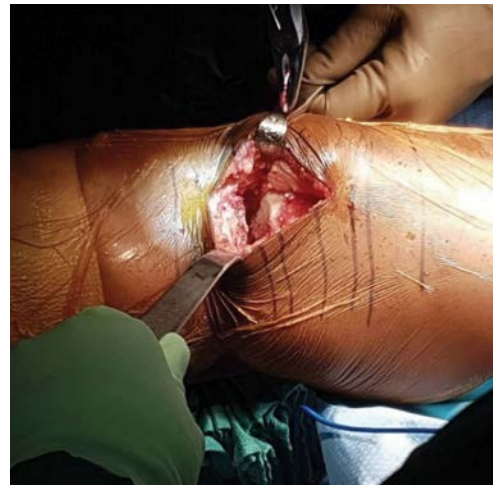

Figure 7. The knee after completing and removing the femoral bone cut.

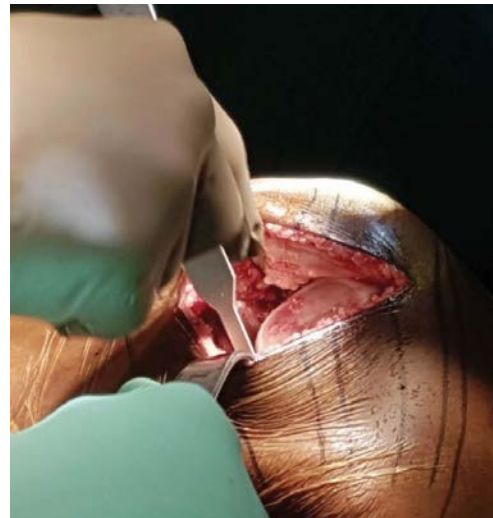


Figure 8. Assessing the flexion gap.

The 8 mm and 10 mm spacers should fit in easily and the 12mm spacer should not fit, signifying an approximate 11mm flexion space. The target should be 3 mm of laxity in flexion when placing an 8 mm polyethylene insert. If the knee is tight in flexion, a small free hand resection is made off the posterior condyle (Figure 9).

Femoral Sizing and Preparation

To determine the appropriate femoral size, the distal femoral tidemark is clearly identified anteriorly. The correct position of the anterior margin of the implant is at least 1mm posterior to the tidemark. The 2 mm end of the 2/3mm testing spacer ('popsicle stick') is placed under the femoral sizing block and the tibial resection is used as a guide for the degree of femoral component external rotation (Figure 10). The correct position is at least 1 mm under the tidemark. Once the correct femoral size has been selected, the cutting block is secured with one screw pin proximally and a second pin laterally towards the notch and two lug holes are drilled into the distal femur (Figure 11). The remaining femoral bone cuts are then made with a small oscillating saw (Figure 12), after

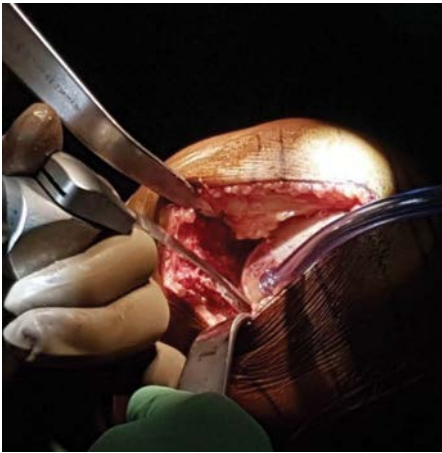


Figure 9. Making a free hand cut off the posterior condyle if tight in flexion.

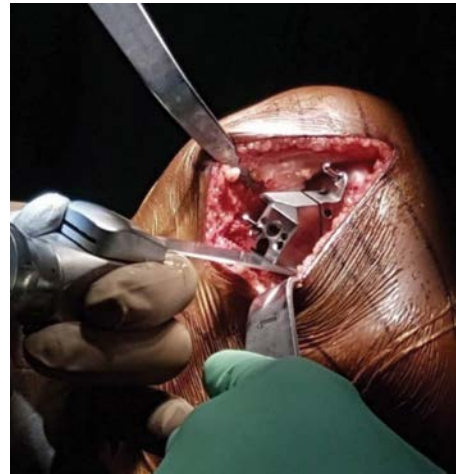


Figure 12. Making the remaining femoral bone cuts through the cutting jig.

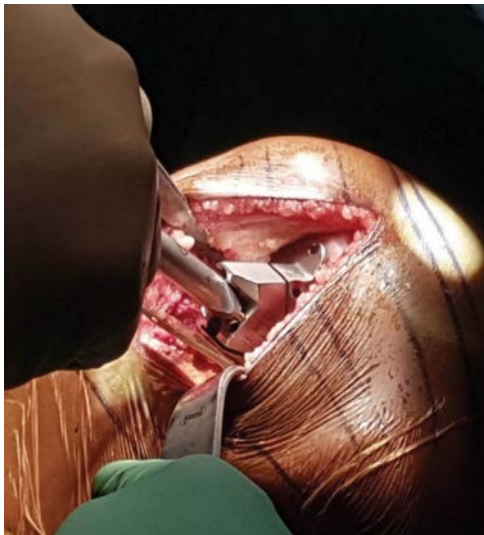

Figure 10. Placing the femoral sizing block using the popsicle stick to help control rotation.

which the femoral cutting block and pins are removed; any incomplete resections are completed with a sagittal saw. All resections are removed with a ½ inch curved osteotome and Kocher.

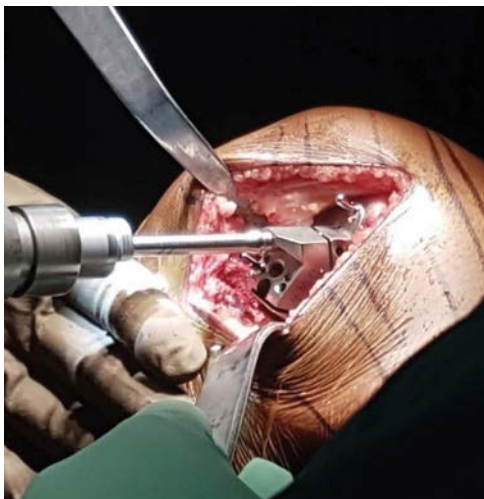

Figure 11. Punching the femoral sizing block with a drill.

Medial Meniscus Removal

The leg is placed in extension with a towel bump placed under the proximal tibia. A rake is placed on the medial skin flap and a knee joint retractor is placed on the patella. The remainder of the meniscus is removed while bending the bovie tip and using a semi-circular motion along the length of the meniscus.

Tibial Sizing and Preparation

The leg is flexed with a posterior cruciate ligament (PCL) retractor placed medially and a single prong retractor in the intercondylar notch. The tibia is sized with paddles; first medial-lateral and then anterior-posterior with a hook (Figure 13). A sagittal saw is then used to make a groove into the lateral aspect of the tibial plateau slightly anteriorly (Figure 14), which will be used for the keel of the tibial implant. An offset impactor is used to move the trial tibial tray into position, using the groove and adjusting its posterior placement to ensure complete anteroposterior and mediolateral coverage of the tibia without overhang (Figure 15).

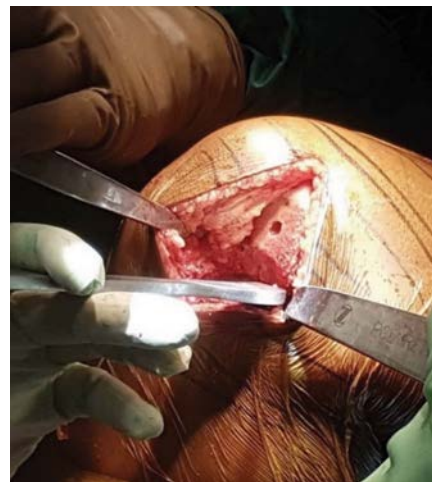

Figure 13. Sizing the tibia with a paddle.

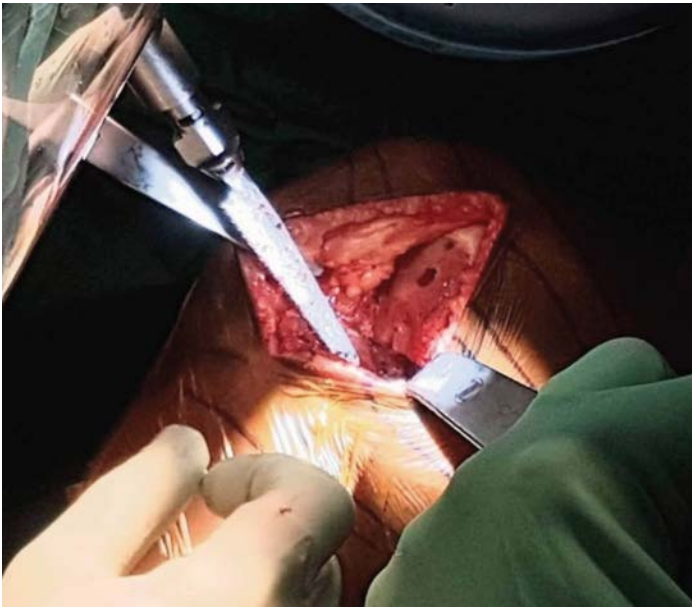


Figure 14. Making a groove in the anterior lateral aspect of the tibial plateau.

Final Gap Assessment, Rotation Adjustment and Tibial Preparation

The knee is then placed in flexion and valgus for placement of the femoral trial component (Figure 16). Next, the 8 mm plastic tibial trial polyethylene insert is placed between the components (Figure 17). The overall alignment is assessed as well as the flexion and extension gaps using the 2-3mm popsicle stick. The 2 mm and 3 mm edge of the stick should be able to fit into the knee while in flexion (Figure 18), and only the 2 mm edge should be able to be placed while the knee is extension (Figure 19). If the rotation of the femur needs to be adjusted at this stage of the procedure, a ¼ inch curved osteotome is used to move bone from the bottom femoral lug hole to change the rotation. The bone is moved from lateral to

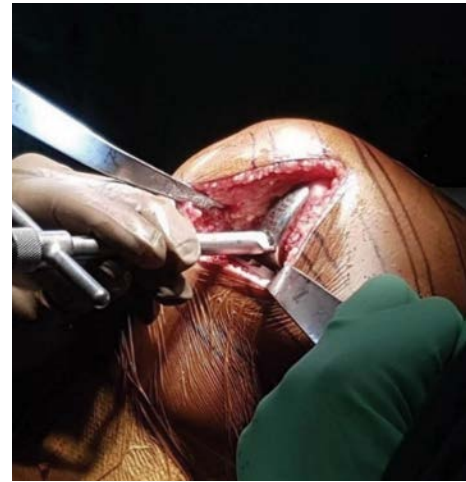

Figure 16. Impacting femoral trial component.

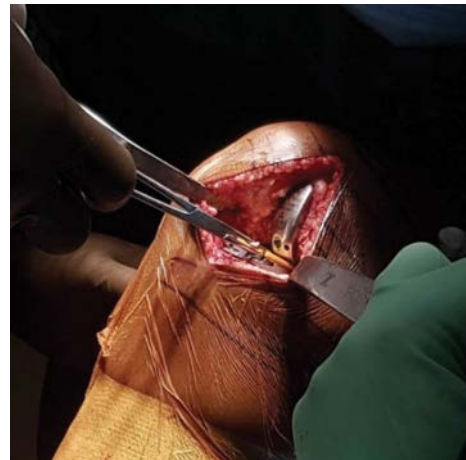

Figure 17. Placing the plastic trial tibial insert.

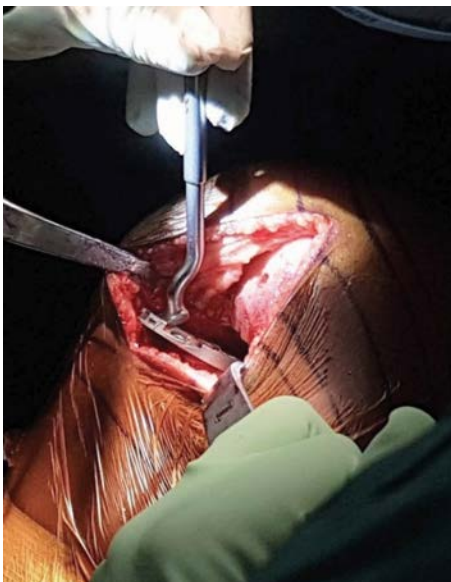

Figure 15. Placing the tibial trial sizing tray, avoiding overhang.

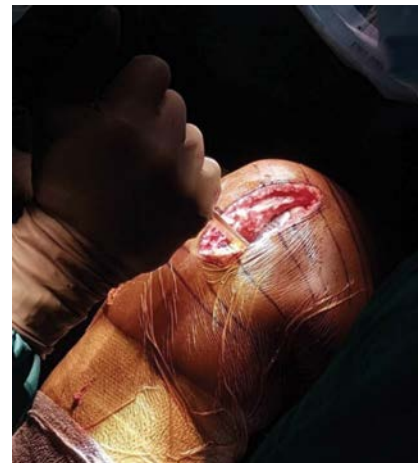

Figure 18. Trialing the 3mm popsicle stick in the knee while in flexion

medial if more external rotation is desired, or from medial to lateral if more internal rotation is desired.

Once rotation and alignment are adequate, the femoral trial and tibial plastic trial insert are removed, and a small drill bit is

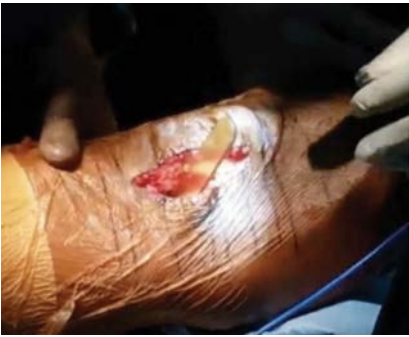

Figure 19. Trialing the 2mm popsicle stick in the knee while in extension and valgus.

used to hold the tibial tray in place (Figure 20). A drill is used to then punch two holes through the trial insert into the tibia (Figure 21) and the drill bit and trial tibial tray are removed.

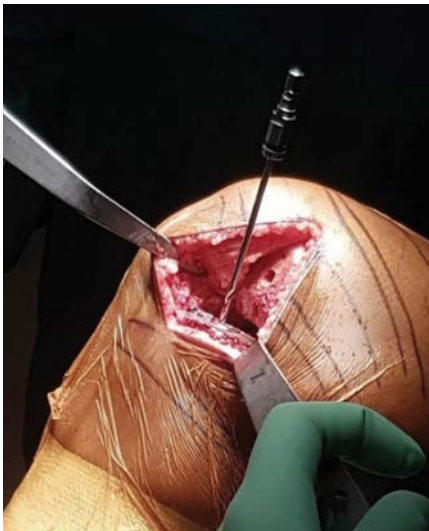

Figure 20. A drill bit holds the trial tibial tray after the femoral component and plastic insert are removed.

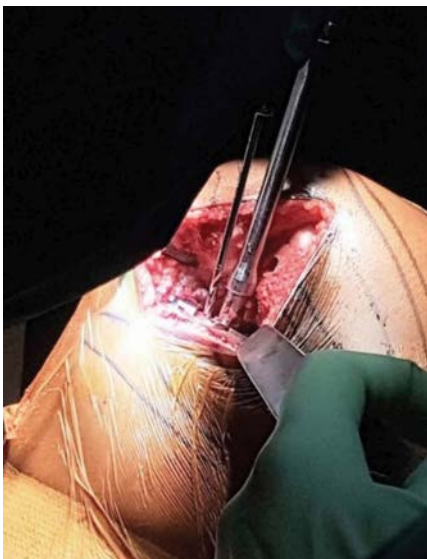


Figure 21. Punching two holes into the tibia through the trial tibial tray.

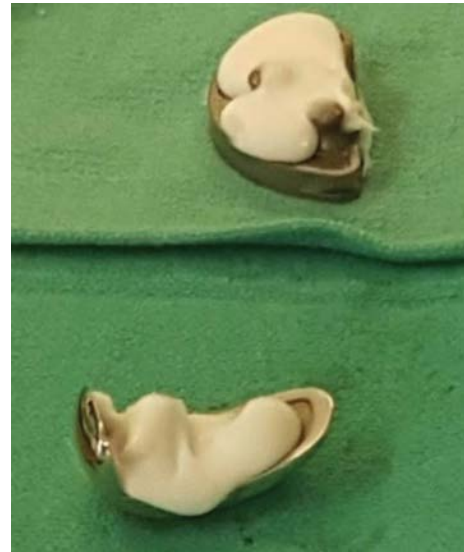

Figure 22. Cement is placed on the components prior to insertion.

Cementation, Final Implantation and Closure

While the cement is mixing, a 0.25% Marcaine solution is injected into the space between the capsule and the synovium, as well as into the medial femoral periosteum. The knee is then thoroughly irrigated. A 3.2 drill bit is then used to create holes in sclerotic surfaces and the bone surface is dried.

The entire surgical team then changes their gloves and cement is placed onto the femoral and tibial components prior to placing them on the bone (Figure 22), with the posterior aspect of the tibial implant having slightly less cement than the anterior aspect. A generous amount of cement should then be placed onto the tibia and a $\frac{3}{4}$ inch osteotome is used to pressurize the cement from posterior to anterior to get good cement inter-digitation. The offset impactor is then used to place the tibial tray on the bone and the $\frac{3}{4}$ inch osteotome is again used to further pressurize the cement, directing force from posterior to anterior, after which the tibial tray is impacted gently into place.

All extruded cement is meticulously removed while the knee is placed in flexion and valgus, which allows for good exposure of both the tibia and femur. Excess cement should be removed in a systematic fashion, utilizing the following steps:

- Remove cement from junction of tibial tray and bone ridge medially
- Remove cement from lateral wall above the tibial component from posterior to anterior
- Remove cement from posterolaterally towards the notch using the golf club tool
- Finally, make several sweeps with the golf club tool, moving posteromedially to anteromedially to ensure all remaining cement has been removed.

The femoral component is then impacted into place and excess cement is once again removed. Make sure to move the incision window medially and then laterally in order to maximize exposure and facilitate cement removal. The

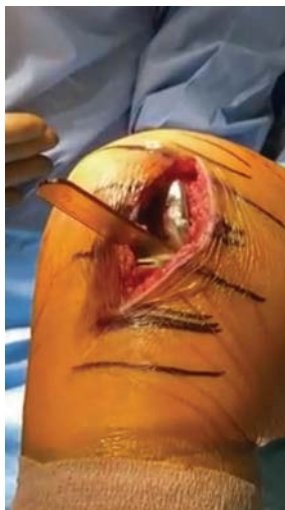

Figure 23. Final components in place with popsicle stick inserted during cement curing.

polyethylene insert is then placed on the tibial tray, making sure that the hand is not inadvertently raised during this maneuver, so as to avoid lifting off the tibial tray during insertion. A bump is placed under the tibia (the knee is now in 30° of flexion) and the 2 mm side of the popsicle stick is inserted between the polyethylene and femoral component while allowing the cement to cure (Figure 23).

The knee is then closed in a layered fashion, with 1-0 vicryl figure-of-eight sutures or a running quill suture for the arthrotomy, followed by 2-0 vicryl for the subcutaneous layer and a running 3-0 monocryl subcuticular closure, followed by skin glue. A hydrofiber dressing is used to cover the incision and the entire leg is wrapped in a large ACE bandage from the foot to the groin.

Post-operative Protocol

Post-operatively, the patient is given 6 weeks of 81mg of aspirin twice daily to prevent thromboembolism. Rapid recovery (23-hour admission) patients are given two doses

of intravenous antibiotics post-operatively. Outpatients are only administered a single dose pre-operatively. Patients are made weightbearing as tolerated immediately with no range of motion restrictions and should begin physical therapy as an outpatient on post-operative day #1 or 2. The first follow-up visit is 2 weeks after surgery, at which time the surgical dressing is removed.

Case Report and Discussion

A 67-year-old male retired DEA officer initially presented to our clinic complaining of isolated medial-sided knee pain for the past 4 years. He had failed conservative treatment including anti-inflammatory medications, bracing, physical therapy and cortisone injections. On physical examination, the patient had range of motion of 0 degrees to 130 degrees; there was no pain with patellar provocative maneuvers and a negative Lachman test. The knee corrected to neutral with a valgus stress.

Pre-operative radiographs (Figure 24), demonstrated isolated medial compartment arthritis with well-preserved lateral and patellofemoral compartments. After a discussion of the risks, alternatives and benefits of the procedure, he elected to undergo UKA.

At latest follow-up at 2 years, his medial pain was completely resolved, and he had returned to his previous level of function. The post-operative radiographs (Figure 25), demonstrate well placed implants without any evidence of component migration, subsidence or loosening. Overall, the patient was so satisfied with his outcome that he elected to have the same procedure performed on his contralateral side.

Unicompartmental knee arthroplasty is effective for the treatment of isolated single compartment knee osteoarthritis, with survival rates greater than 90% at 10 years.¹¹ For the appropriately indicated patient who wishes to undergo a less invasive procedure with easier recovery, a properly performed UKA is an excellent surgical option.

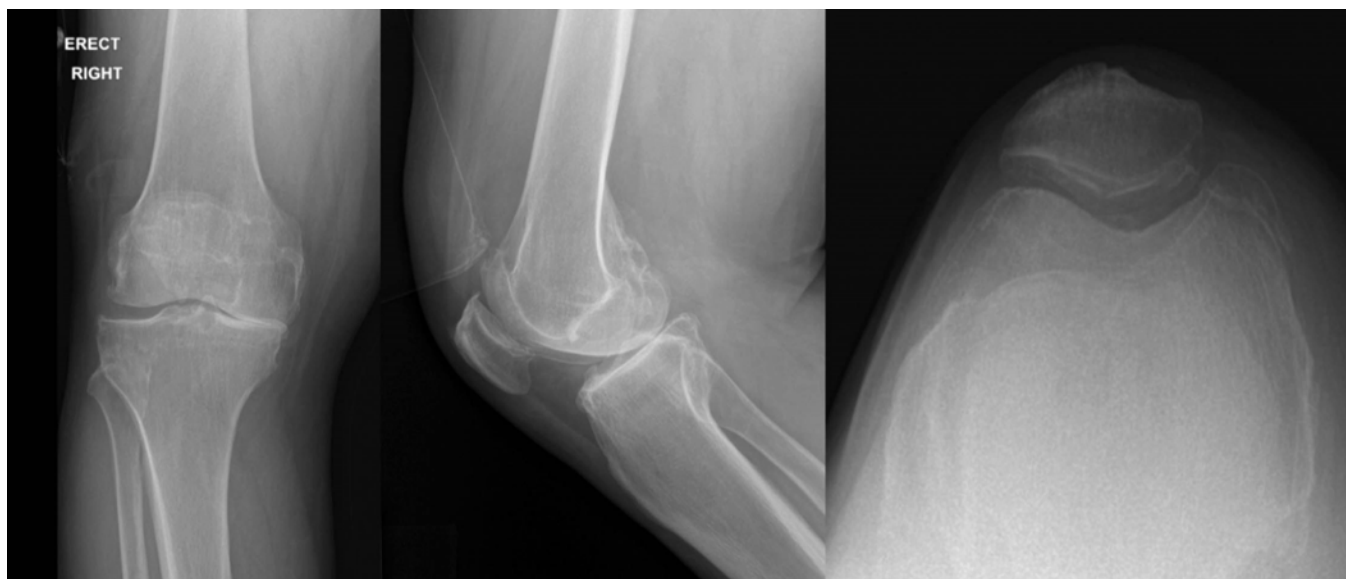


Figure 24. Pre-operative AP, lateral and merchant view radiographs of a patient with isolated medial compartment arthritis.

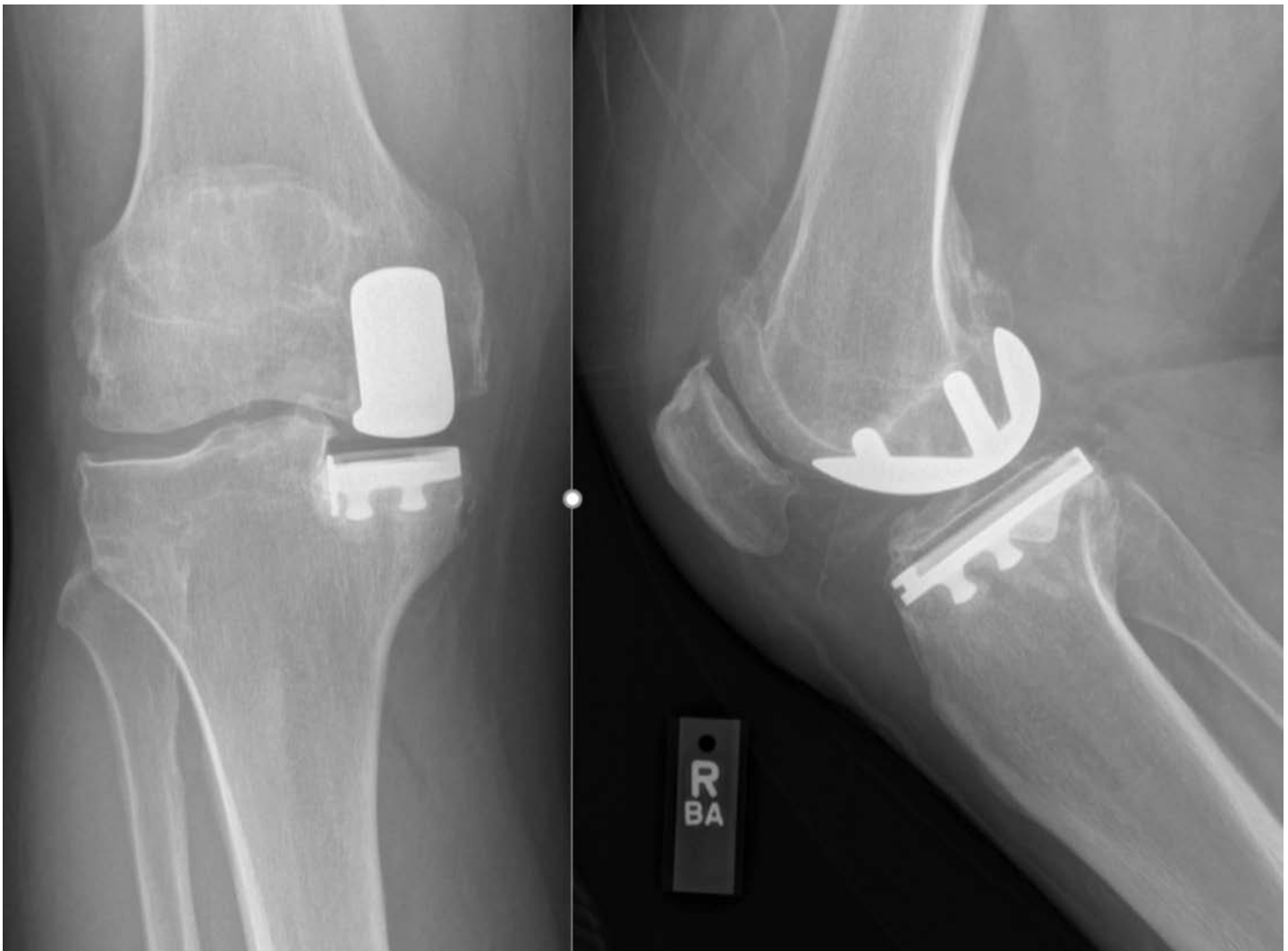

Figure 25. Post-operative AP and lateral view radiographs of the patient shown in Figure 24, after medial UKA.

References

- Jennings JM, Kleeman-Forsthuber LT, Bolognesi MP.** Medial Unicompartmental Arthroplasty of the Knee. *J Am Acad Orthop Surg.* 2019 Mar 1;27(5):166-176.
- Lombardi AV Jr, Berend KR, Walter CA, et al.** Is Recovery Faster for Mobile-Bearing Unicompartmental Than Total Knee Arthroplasty? *Clin Orthop Related Res.* 2009 Jun;467(6):1450-7.
- Siman H, Kamath AF, Carrillo N, et al.** Unicompartmental Knee Arthroplasty vs Total Knee Arthroplasty for Medial Compartment Arthritis in Patients Older Than 75 Years: Comparable Reoperation, Revision and Complication Rates. *J Arthroplasty.* 2017 Jun;32(6):1792-1797.
- Vasso M, Corona K, D'Apolito R, et al.** Unicompartmental Knee Arthroplasty: Modes of Failure and Conversion to Total Knee Arthroplasty. *Joints.* 2017 Mar;5(1):44-50.
- Chin BZ, Tan SSH, Chua KCX, et al.** Robot-Assisted Versus Conventional Total and Unicompartmental Knee Arthroplasty: A Meta-Analysis of Radiological and Functional Outcomes. *J Knee Surg.* 2020 Mar 17 [Epub Ahead of Print].
- St Mart JP, de Steiger RN, Cuthbert A, et al.** The Three-Year Survivorship of Robotically Assisted Versus Non-Robotically Assisted Unicompartmental Knee Arthroplasty. *Bone Joint J.* 2020 Mar;102-B(3):319-328.
- Bell SW, Anthony I, Jones B, et al.** Improved Accuracy of Component Positioning with Robotic-Assisted Unicompartmental Knee Arthroplasty: Data from a Prospective, Randomized Controlled Study. *J Bone Joint Surg Am.* 2016 Apr 20;98(8):627-35.
- Winnock de Grave P, Luyckx T, Ryckaert A, et al.** Medial Unicompartmental Knee Arthroplasty with a Fixed Bearing Implant. *JBJS Essent Surg Tech.* 2019 Aug 14;9(3):e26.
- Kozinn SC, Scott R.** Unicompartmental Knee Arthroplasty. *J Bone Joint Surg Am.* 1989 Jan;71(1):145-50.
- Hamilton TW, Pandit HG, Jenkins C, et al.** Evidence-Based Indications for Mobile-Bearing Unicompartmental Knee Arthroplasty in a Consecutive Cohort of Thousand Knees. *J Arthroplasty.* 2017 Jun;32(6):1779-1785.
- Kim KT.** Unicompartmental Knee Arthroplasty. *Knee Surg Related Res.* 2018 Mar;30(1):1-2.