



Dynamic Changes in the Porcine Meniscus and Articular Cartilage After Meniscal Injury

Sonia Bansal, BA^{1,2}
Liane M Miller, MD^{1,2}
Jay M Patel, PhD^{1,2}
Kamiel S Saleh, BA^{1,2}
Brendan D Stoeckl, MSE^{1,2}
Dawn M Elliott, PhD³
Michael W Hast, PhD⁴
Miltiadis H Zgonis, MD^{1,2}
Robert L Mauck, PhD^{1,2}

¹McKay Orthopaedic Research Laboratory
University of Pennsylvania
Philadelphia, PA

²Translational Musculoskeletal
Research Center
Philadelphia VA Medical Center
Philadelphia, PA

³Multi-Scale Fiber-Reinforced Tissue
Biomechanics Laboratory
University of Delaware
Newark, DE

⁴Biedermann Laboratory for
Orthopaedic Research
University of Pennsylvania
Philadelphia, PA

Introduction

The meniscus is an integral load-bearing tissue in the knee¹ that is commonly injured.² The functional role of the meniscus has been widely studied in small animal models in service of understanding controlled joint degradation after meniscus destabilization.³ However, these studies focus primarily on the cartilage and joint rather than on the impact of injury on the meniscus itself due to the small size of the rodent meniscus. A number of studies suggest, however, that even smaller injuries may have long term deleterious effects on the joint, as is evidenced by the early onset of OA in humans with small excisions of meniscus tissue to treat tears in the inner zone.^{4,5} While post-injury joint degeneration is an established clinical problem, progression of disease in the meniscus itself is not well studied. In previous work, we evaluated the short-term (one month) effects of arthroscopic meniscus injury in a Yucatan minipig model on whole joint, meniscus, and cartilage mechanics, and on meniscus and cartilage histopathology. That study indicated that destabilization of the medial meniscus (DMM) via detachment of the anterior horn led to altered transfer of load across the tibial plateau, decreased cartilage mechanics, and a loss of proteoglycans in both the cartilage and the meniscus at this early time point. Conversely, a longitudinal vertical defect, which maintains meniscus-mediated load transfer in the knee, resulted in few changes in any of these quantitative outcomes. Here, we evaluated the longer term (three and six month) outcomes of these meniscal injuries in order to evaluate the progression of multiscale changes of the meniscus and joint.

Methods

Surgical experimental design

Juvenile (6 month old) Yucatan minipigs underwent bilateral arthroscopic surgery and each limb received one of the following injuries to the medial meniscus: sham, DMM via complete transection of the anterior attachment, or a vertical longitudinal tear (1/5 arc length, red-white zone, n = 5-7/group/time point). Animals were euthanized at one, three, or six months following surgery, and joints were harvested for a series of macro-, meso-, and micro-scale analyses.

Macroscopic load transfer and joint degeneration

In macro-scale tests, intact joints were compressed to 1x body weight (400 N) at a flexion angle of 45° using a custom rig and universal test frame. Thin film pressure sensors (TekScan #6900-110) were inserted into the joint to measure load transfer through the medial compartment.⁶ Next, joints were assessed for macroscopic changes to the meniscus and for cartilage wear (using India ink).

Meniscus mechanics and ECM remodeling

Subsequently, medial menisci were harvested and sectioned (350 micron thickness in the horizontal plane within the body) and trimmed to a dog bone shape for mechanical tensile testing (tensile ramp to failure, 0.1% strain/sec). Menisci were also sectioned (16 micron thickness, vertical plane in the anterior and posterior horns) for histological analysis of proteoglycans (PGs, Safranin O/Fast Green).

Osteochondral evaluation

Osteochondral segments from the medial tibial plateau were isolated and indented using a spherical indenter (2 mm diameter) to determine cartilage mechanical properties in the regions covered by the meniscus and cartilage.⁷ Next, microCT analysis of the subchondral bone was performed. Samples were then decalcified, embedded, sectioned, and stained for PGs (Safranin O/Fast Green).⁸ Sections were graded using the OARSI scoring method⁹ by five blinded observers (scale: 0-25, best to worst).

Results

Macroscopic load transfer and joint degeneration

When joint-level mechanics were assessed, DMM-treated joints showed an increase in peak contact pressure and decreased contact area on the tibial plateau compared to Sham and Vertical samples at one month. This effect did not persist to three or six months (Fig. 1). In sham-operated joints, menisci showed no macroscopic evidence of degeneration at any time point. However, DMM-treated joints showed evidence of degeneration at each time point, with anterior fibrovascular scars forming at the injury site

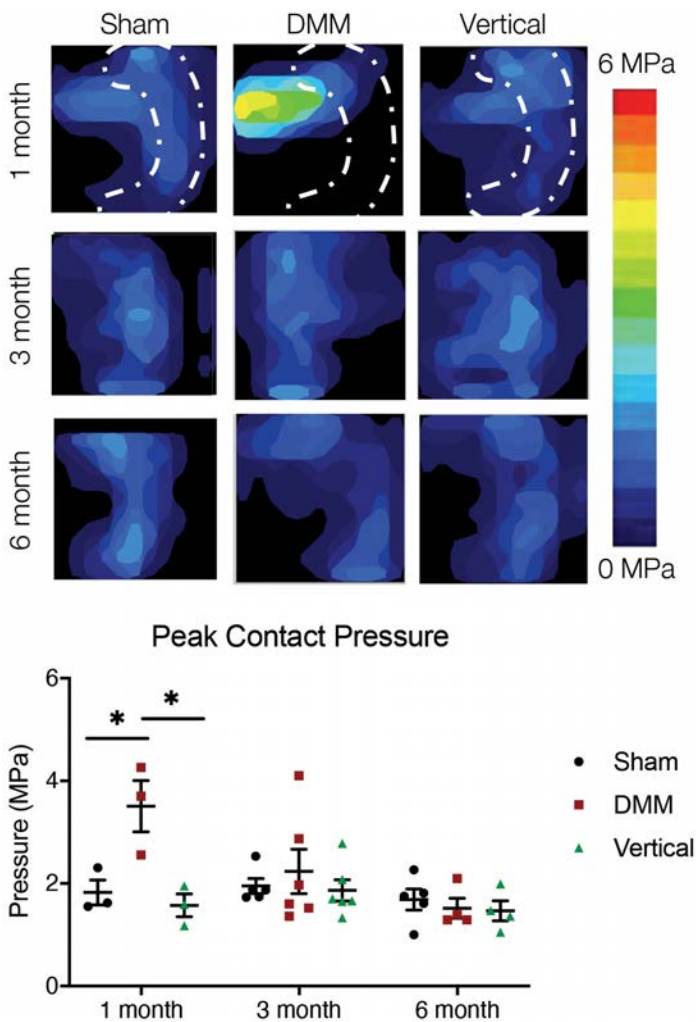


Figure 1. Contact pressure maps (top) and quantification of peak contact pressure.

in most samples at all time points and meniscal narrowing present at both 3 and 6 months. Vertical tears were visible in the majority of samples at 3 and 6 months; this did not result in marked degeneration of the cartilage surfaces (data not shown).

Meniscus mechanics and ECM remodeling

Bulk tensile mechanics were not significantly different across treatment groups at each time point (data not shown). However, DMM-treated menisci had less intense staining for PGs compared to sham-operated menisci at one month, and this was sustained through to both three and six months. Menisci subjected to a vertical tear did not show a decrease in staining compared to sham at six months though the tear was visible at three and six months (Fig. 2).

Osteochondral evaluation

While there were no changes to subchondral bone (not shown), cartilage indentation modulus in the cartilage-meniscus contact region decreased in DMM operated joints at one month and continued through three months. Interestingly, joints in which menisci were subjected to a vertical tear

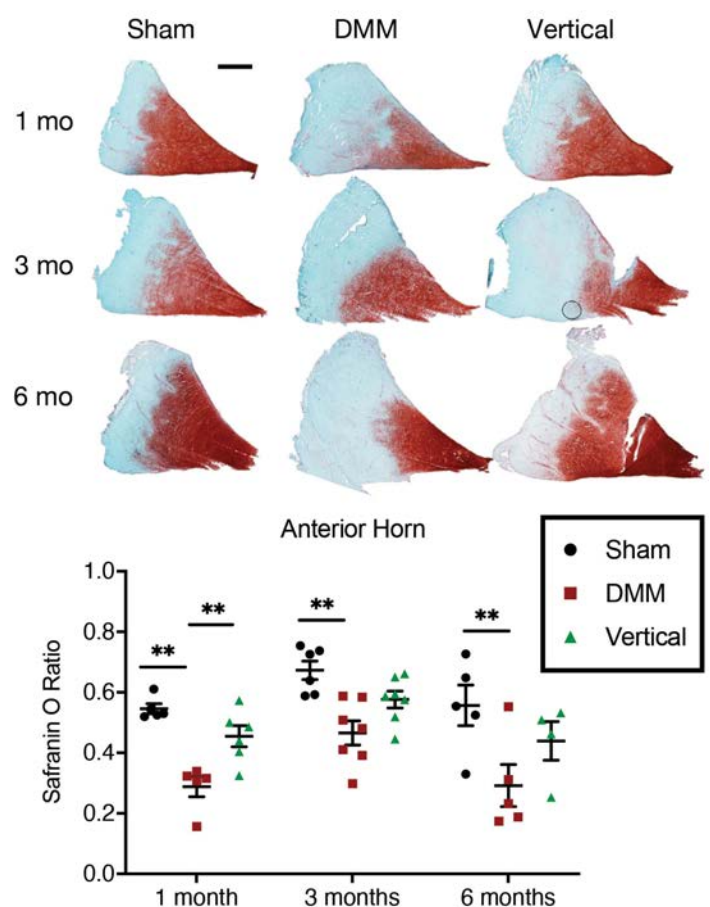


Figure 2. Safranin-O/Fast Green histology of the anterior horn of the meniscus (scale = 2 mm, top) and quantification.

showed no change in cartilage mechanics at 1 month, but a decrease in indentation modulus at 3 months. These detrimental changes resolved by 6 months in both treatment groups (Fig. 3). OARS1 scoring significantly increased, indicating osteoarthritic changes, in DMM joints at one month. This effect was somewhat attenuated, but remained significantly elevated, at three months. Vertical tears did not result in a change in OARS1 scoring at either time point (data not shown)

Discussion

This study investigated meniscal and joint remodeling in a minimally invasive (arthroscopic) large animal surgical model of meniscus injury. Interestingly, we found that load transfer through the meniscus was significantly altered at 1 month post-DMM, but that this had returned to sham levels by 3 and 6 months. This was potentially due to a wide, fibrovascular scar tissue noted at the site of detachment, which had developed at 1 month and matured by 3 months to restore load transmission. The effects of DMM-injury and early unloading caused a transient decrease in cartilage mechanics in the tibial cartilage, as well as increased cartilage histopathology scores at 3 months. Interestingly, the meniscus showed sustained and worsening loss of proteoglycan content after injury in DMM menisci and in menisci subjected to vertical tears at

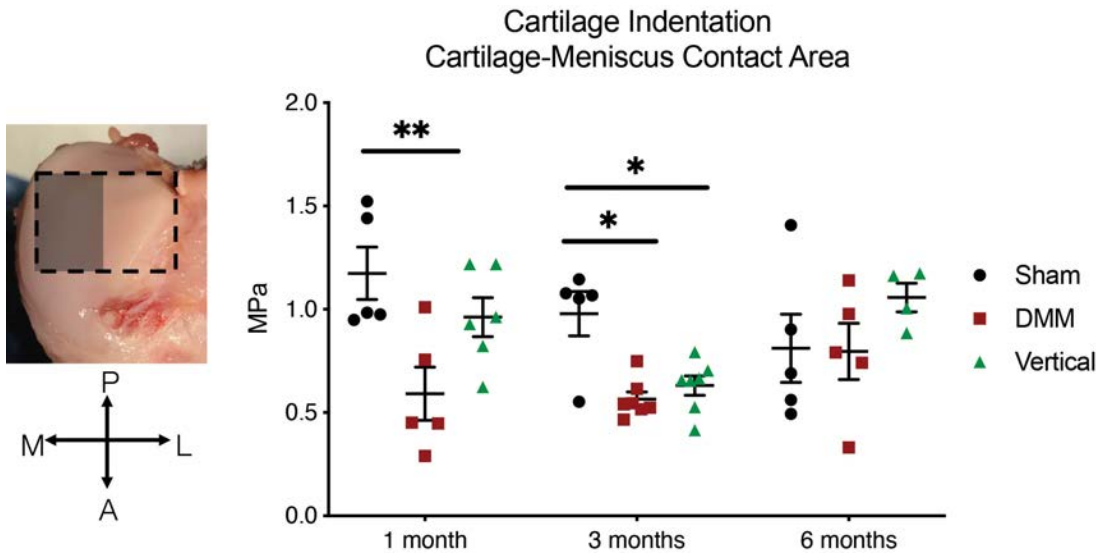


Figure 3. Cartilage-Meniscus contact area and cartilage indentation modulus in this region.

6 months. This may indicate a dynamic remodeling process, wherein the healing of the severed meniscal attachment in the DMM group restored load transfer and slowed the rate of joint degeneration compared to sustained degenerative changes in the meniscus. Current work is investigating a wider range of outcome measures of cartilage and meniscal post-injury remodeling in these animals to determine the scope of these changes. Understanding the progression of joint disease after meniscal injury in this large animal model may improve surgical decision making and inform novel repair strategies to combat osteoarthritis after meniscal tear.

Acknowledgments

This work was supported by the Department of Veterans Affairs (I01 RX000174) and the National Institutes of Health (R01 EB002425, R01 AR056624, and T32 AR007132).

References

1. Makris, EA et al., *Biomater*, 32:7411, 2011.
2. Mordecai, S, *World J of Orth*, 5:233, 2014.
3. Glasson, SS et al., *OA&C*, 15:1061, 2007.
4. Roos, H et al., *OA&C*, 3:261, 1995.
5. Lohmander, LS et al., *AJSM*, 35:1756, 2007.
6. Bedi, A et al., *JBJS*, 92:1398, 2010.
7. Meloni, GR et al., *Tissue Eng*, 23:663, 2017.
8. Sennett, ML et al., *JOR*, 36:2648, 2018.
9. Little, CB et al., *OA&C*, 18:S80, 2010.
10. Waller, KA et al., *AJSM*, 45:1512, 2017.
11. Luther, JK et al., *Vet Surg*, 38:520, 2009.