

Aggressive Surgical Management of Chronic Osteomyelitis

PHILIP Z. WIRGANOWICZ, M.D.

Abstract: Chronic osteomyelitis has classically been characterized by having variable periods of quiescence followed by flare-ups that may continue throughout the life of the individual. The consequences of this infection range from the minor nuisance of a draining tract, to a pathologic fracture at the infected site, and possible transformation to a malignant state. The chronicity is due in part to the avascular nature of the sequestrum as well as the porosity of bone. Despite advances in antibiotic therapy, chronic osteomyelitis has been difficult to cure. The historical mainstay of treatment has been repeated incision and drainage of the involved bone and sequestrum and long-term antibiotics. However, this has led to a dismal success rate since the infecting organism can take advantage of the porosity of bone and remain in the interstices even after vigorous irrigation. Excellent end results in treating chronic osteomyelitis have been achieved with aggressive surgical management and pathogen-specific antibiotics. The surgical management includes serial debridements followed by local or microvascular surgical muscle flaps for soft tissue coverage and bone grafting for structural defects when necessary.

Introduction

The goals in the treatment of chronic osteomyelitis, namely to eradicate the infection and maintain optimum physiologic function for the affected area, have been a difficult challenge for the physician. Antibiotic therapy alone has led to dismal rates of eventual cure. Despite advances in both antibiotics and surgical treatment, the long-term recurrence rate remains at approximately 20–30% [2,15,16,18,29,31,35,47]. As a result, chronic osteomyelitis has generally been characterized as having variable periods of quiescence followed by flare-ups, which may continue throughout the patient's lifetime [9]. The consequences of this infection range from the minor nuisance of a draining tract, to a pathologic fracture at the infected site [34,49], to the possible malignant transformation to squamous cell carcinoma in a draining tract [23,34].

The chronicity of osteomyelitis is multifactorial. The relative avascular and ischemic nature of the infected region and sequestrum produces an area of lowered oxygen tension as well as an area that antibiotics cannot penetrate. The lowered oxygen tension effectively reduces the bactericidal activities of polymorpholeukocytes [40] and also favors the conversion of a previously aerobic infection to one that is anaerobic. The consequence of the ischemia within

the sequestrum and surrounding infected areas is a lowering of the antibiotic levels in these sites [12,13,17,39,41,49]. This may lead to ineffective antibiotic concentrations at the site of infection despite serum levels indicating therapeutic concentrations. The increased frequency of antibiotic usage as well as the wider variety of antibiotics has resulted in the emergence of resistant organisms, often to multiple antibiotics [9,34]. In addition, chronic osteomyelitis tends to be polymicrobial both in terms of aerobic and anaerobic microorganisms [24,26,29,40,51,52]. An open wound or sinus tract is always a potential source of superinfection [9]. In instances where proper antibiotic therapy was started to treat the organisms initially recovered from the infected site, there is the potential for successive infections with more virulent, more resistant, or opportunistic organisms.

It is apparent in the face of chronic osteomyelitis that antibiotics alone are ineffective. The role of surgery has been primarily directed at removing all infected material including surrounding scar tissue in order to restore adequate blood flow to the area [42]. However, the dead space created by the removal of the sequestrum and scar increases the likelihood of the cavity becoming reinfected [12,13,17,25,29,46]. Multiple methods have been described to eliminate this dead space; most commonly, bone grafting followed by primary or secondary closure, skin grafting [1,4,8,14,17,22,28,30,32,33,43], and muscle flaps with or without bone grafting [21,25,36,37,41,45,50]. All of these techniques require meticulous surgical technique, but have proven successful when carried out in the proper setting.

The reason for the high rate of long-term recurrence is controversial, but it is most likely due to several factors. Primary considerations include (1) inadequate surgical debridement in removing the entire sequestrum, (2) decreased blood flow as a result of the initial insult or secondary to operative dissection resulting in diminished healing capacity and resistance to recurrent infection, (3) scar tissue or residual dead space serving as a nidus for recurrent infection, and (4) the presence of a mixed aerobic and anaerobic infection. With these factors in mind and extensive review of past historical and contemporary treatment modalities, thorough surgical debridement remains the sine-qua-non of treatment. This process may be taken one step further by treating patients in a serial operative fashion. Since chronic osteomyelitis is generally a localized process with a high likelihood of recurrence if inadequately treated, the approach to treatment should be considered analogous to that of the treatment of a benign, aggressive bone tumor, such as

From the Department of Orthopaedic Surgery, University of Pennsylvania School of Medicine, Philadelphia, PA.
Address correspondence to: Philip Z. Wirganowicz, M.D., Department of Orthopaedic Surgery, 3400 Spruce Street, Philadelphia, PA 19104.

a giant cell tumor. Such techniques in the treatment of giant cell tumors have been previously described with excellent end results [19].

Methods

The preoperative evaluation should include an initial complete blood count with differential, erythrocyte sedimentation rate, C-reactive protein, standard blood chemistries and coagulation studies, electrocardiogram (EKG), chest roentgenogram, roentgenogram of the area of involvement, and bone scan (Fig. 1A,B). However, in many cases of chronic osteomyelitis, it is not unusual to find normal or near-normal laboratory values. Computed tomography (CT) and magnetic resonance imaging (MRI) scans also help delineate the extent of bone infection and sequestrum. At surgery, multiple aerobic, anaerobic, fungal, and tuberculin cultures are obtained and patients are begun empirically on cefazolin or a more specific antibiotic if that information is available preoperatively. After culture results are available, the antibiotic regimen is then changed to organism-specific antibiotics. In addition, pathology should be sent with the initial debridement for both frozen and permanent sections.

The site of osteomyelitis is extensively exteriorized using curettes and high-speed burr techniques to be sure that all infected and nonviable bone and soft tissue are removed (Figs. 2 and 4B). Using pulsatile lavage, the wound is cleansed with between 4 and 6 L of sterile normal saline solution containing antibiotics such as Bacitracin/Polymyxin B. Next, the wound is rinsed using full-strength Betadine and hydrogen peroxide while continuing pulsatile lavage. A final washing using sterile normal saline solution follows. The wound is then packed using only saline-soaked gauze without antibiotics or Betadine and the skin is loosely closed to retain the gauze. The patient is taken back to the operating room in 48–72 hours for repeat cultures, debridement, irrigation, and packing. This process is serially repeated until the wound is pink and granulating, all areas of curetted bone show good punctate hemorrhaging, and intraoperative cultures are negative. The wound is closed primarily if possible over suction drains. Figure 3 shows a roentgenogram 2 months following treatment. If the defect in adjacent soft tissues precluded closure, a rotational or free muscle flap with skin grafting is used.

In those instances where the structural integrity of the bone appears compromised, autologous bone grafting can

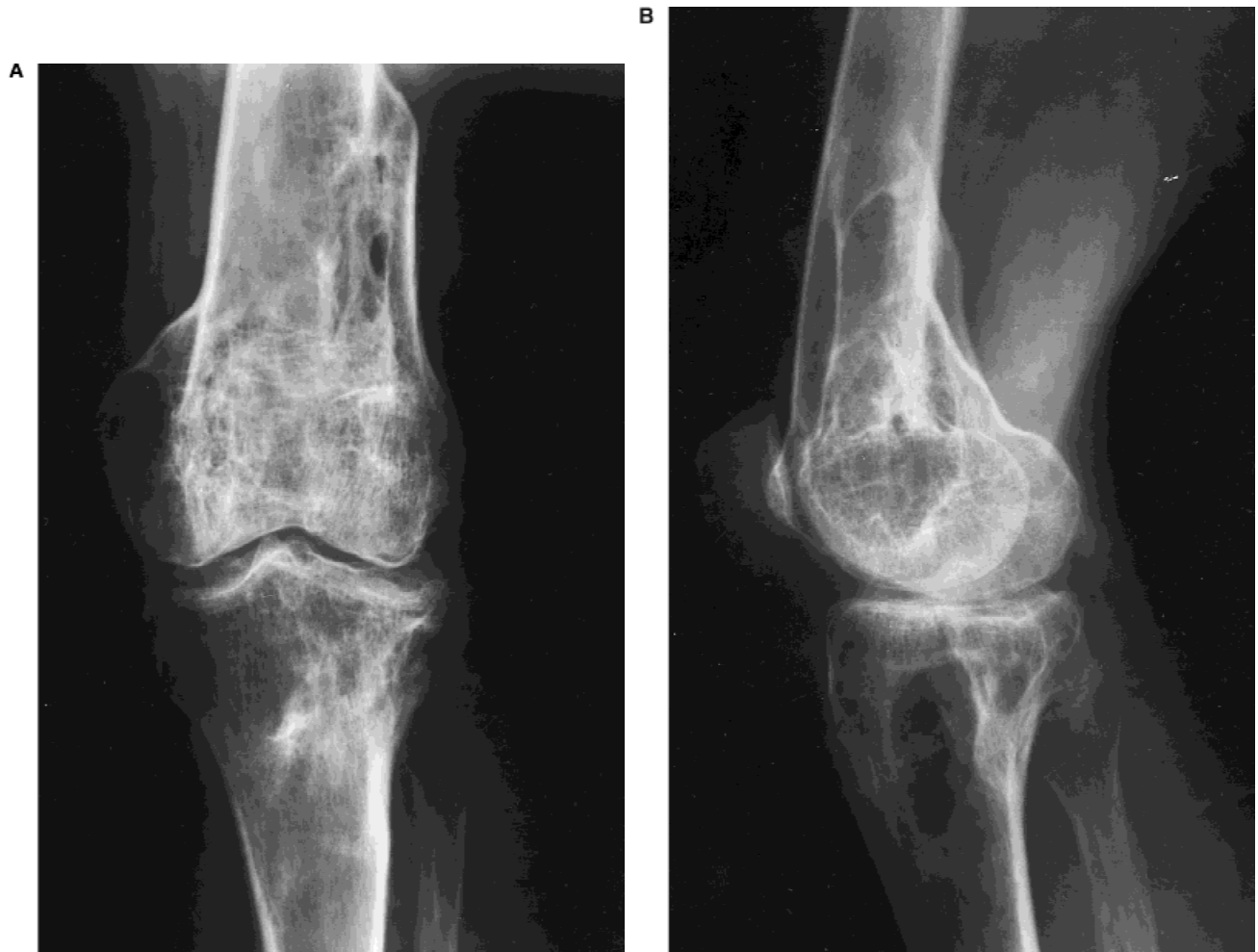

Fig. 1. Preoperative radiographs. **A:** Anteroposterior view shows areas of lucency of medial proximal tibia. **B:** Lateral view shows well-defined lytic region of osteomyelitis.

be performed using the posterior iliac crest (Figs. 3A,B and 4C). Allograft may be mixed with the autologous graft if the volume of the bony defect exceeds the amount of autologous bone obtained. Distraction osteogenesis and the use of synthetic bone grafting substitutes are potential alternative methods of osseous reconstruction.

Parenteral and oral antibiotics are given for an extended period of time. This is generally a period of 3–10 weeks.

Results

In a limited series of patients treated in this fashion, all patients had multiple operative procedures until there was evidence that the infection was eradicated and the wound appeared to be healing [51]. Patients averaged 4.2 debridements (range, three to eight). Two of 13 patients required plastic surgery reconstructive procedures for wound coverage and/or filling of dead space. Each of these also required split thickness skin grafts to cover harvest sites or free muscle pedicle flaps. Two patients had resection of their infected bone: one patient required a talectomy and arthrodesis and the other required hip disarticulation. The disarticulation was necessary due to the extensive nature of her disease, a lack of viable bone stock, and severe osteoporosis. One patient, at the completion of his surgeries, had a

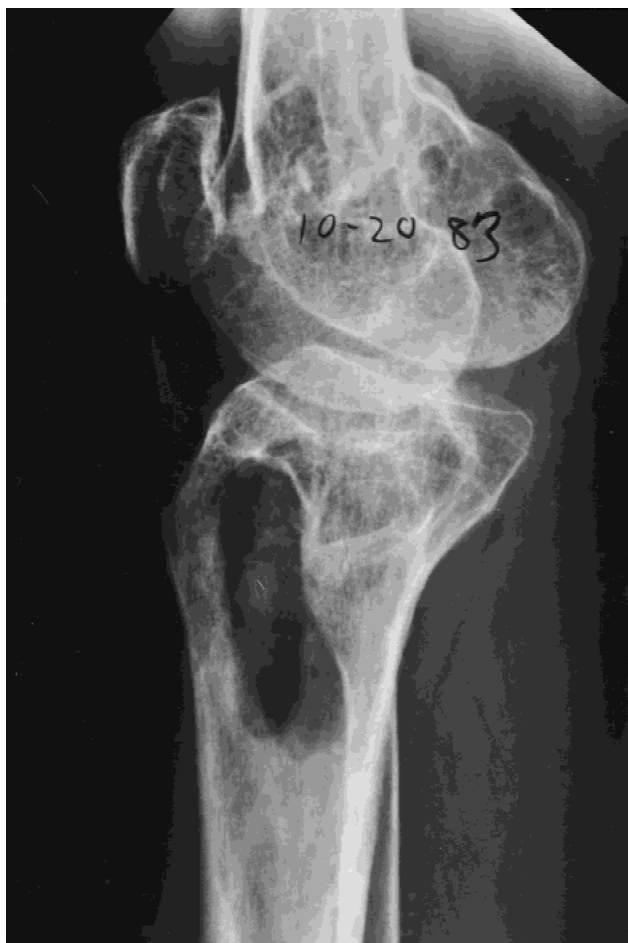

Fig. 2. Lateral radiograph of a patient with osteomyelitis of proximal tibia. This shows wide debridement of the involved area.

5-week trial of hyperbaric oxygenation at an outside hospital to promote soft tissue healing.

In postoperative follow-up (mean 58 months, range 11–89 months), none of the patients have experienced evidence of recurrent osteomyelitis. The one patient who was treated with disarticulation was considered a treatment failure, although this was unavoidable considering the extensive severity and duration of her disease. However, she is pleased with the result since she is no longer encumbered with a painful, malodorous, useless limb.

Discussion

Chronic osteomyelitis has been a difficult problem for the patient and treating physician. The frequent rate of flare-ups requiring multiple hospital admissions, the pain and limitations on activity, and the possible sequelae of the long-term infectious process take their toll on the patient both mentally and physically. For the physician, the recurrence can be frustrating.

The ultimate goal in treatment is to eradicate the infection and to prevent recurrence. However, this has been difficult to achieve for several reasons. Many previous attempts at treatment employed inadequate exteriorization at the site of infection (Fig. 4A), perhaps in the thought of treating the patient as conservatively as possible. This has only resulted in the inadequate removal of necrotic and infected tissue. Other reasons for recurrence include the failure to fill the resulting bony defect, the failure to identify mixed aerobic and anaerobic infections, inadequate or inappropriate antibiotic therapy, and relatively ischemic tissue remaining in the surrounding tissue with a decreased ability to resist infection. As a result of these obstacles in the treatment of chronic osteomyelitis, recurrence has remained at an unacceptably high level of between 20–30%. However, in a Mayo Clinic review there had been a recurrence rate of 61.5% in mixed aerobic/anaerobic osteomyelitis [29], but the pathophysiology behind these results is as yet not clear.

The high level of recurrence has led to multiple alternative treatment methods including maggots, amputation, electrical stimulation, cryotherapy, and hyperbaric oxygenation [5,6,10,11,20,38,48]. The results of these experimental procedures are at best inconclusive.

Another difficulty in measuring the success of treatment is the length of postoperative follow-up. Although many studies showed promising initial results, long-term follow-up data were frequently lacking [7,9,17,30,33,44]. Since the natural course of the disease is characterized as having variable periods of quiescence lasting up to several years, long-term postoperative follow-up is essential in determining the effectiveness of treatment.

Osteomyelitis should be considered a localized process in a segment of bone and is infrequently ubiquitous in its involvement. Therefore, the premise of treatment should be directed toward several objectives. First, the initial curettage should achieve a wide exteriorization to ensure adequate access to the infected bone segment. Second, the patient should undergo serial debridement and irrigation procedures

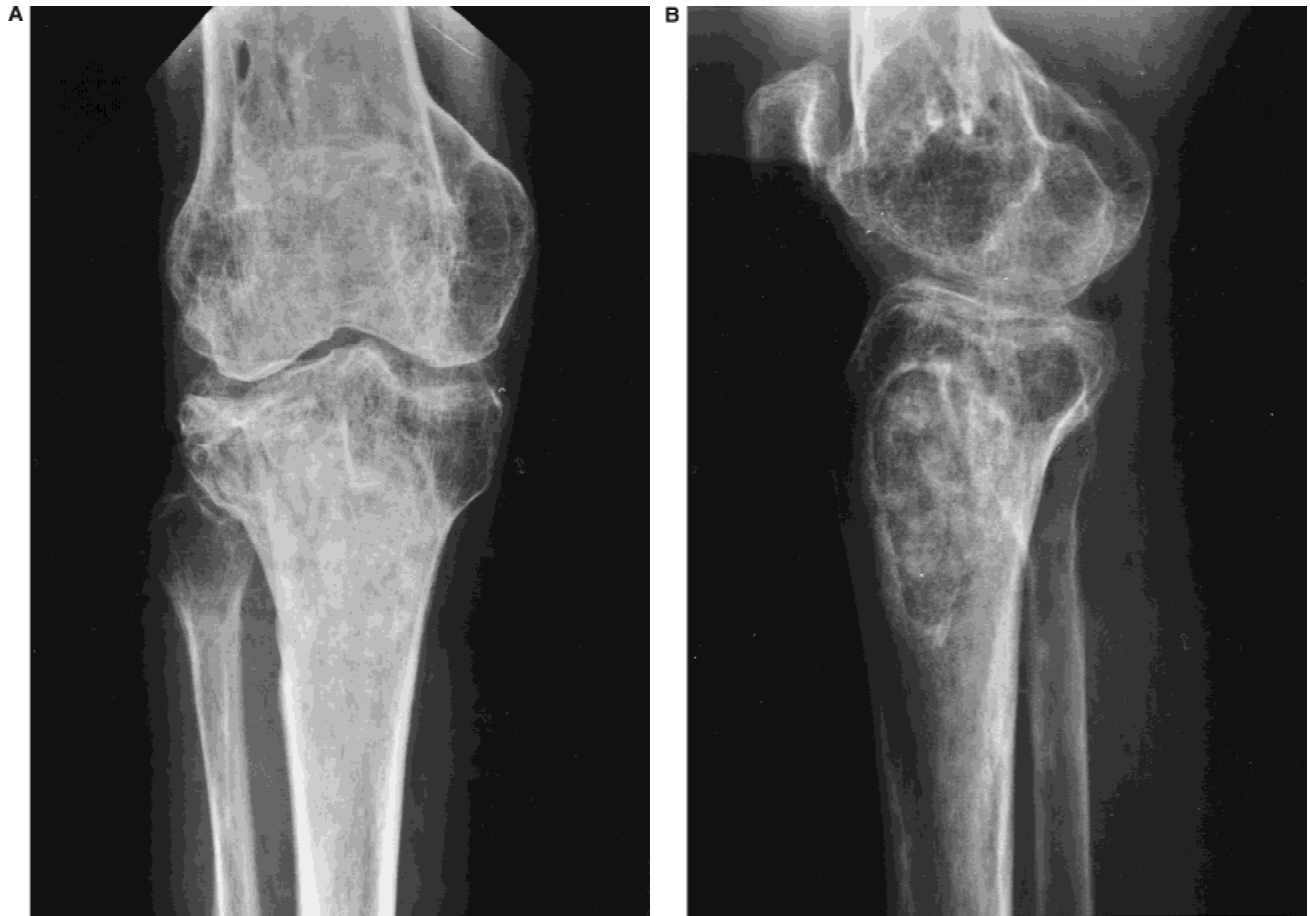

Fig. 3. Patient with osteomyelitis of proximal tibia seven months after treatment. **A:** Anteroposterior view shows no further evidence of recurrent osteomyelitis. **B:** Lateral view showing good incorporation of bone graft in proximal tibia.

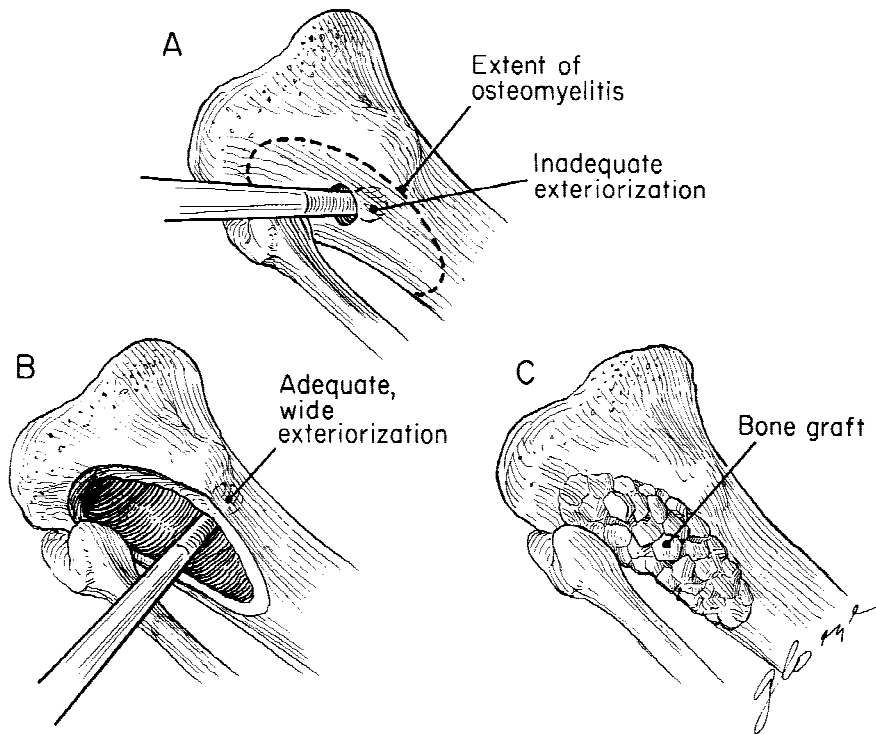


Fig. 4. **A:** Inadequate exteriorization does not allow for complete removal of infected and necrotic material that frequently results in recurrent osteomyelitis. **B:** Wide exteriorization allows access to all areas of the infection ensuring a more thorough debridement. **C:** After there is evidence that the infection has been eradicated, reconstruction techniques such as bone grafting or plastic surgery flaps can be performed.

since infected, nonviable tissue may be difficult to differentiate from healthy tissue at initial debridement. The total number of debridement/irrigation procedures should not be arbitrary; rather endpoint criteria should be evidence that the wound and bone infection have been eradicated by clinical observation and culture results. Third, these debridement and irrigations should be performed in the operating room where there are optimal sterile conditions and the procedure is less painful to the patient than at the bedside. The final washing at each procedure should be done with normal saline and the wounds should not be packed with antibiotic or Betadine-containing gauze or antibiotic-impregnated beads. This may reduce the emergence of resistant organisms. Also, the surgical sites should be closed securely in the operating room and not reopened until the patient is returned to the operating room for the next procedure. Finally, once the infection is cleared, reconstruction of the bone and soft tissue defect should be done using principles similar to the management of a giant cell tumor after an intralesional curettage [19]. This involves using bone grafting and/or muscle flaps to restore structural integrity, to fill the created dead space, and to establish adequate wound coverage and blood supply. It should be emphasized that proper antimicrobial therapy in terms of both organism specificity and duration should be used concomitantly with surgical treatment.

Using these methods, there is a low likelihood of recurrence. In most cases, a functional limb is maintained. Serial operative procedures every 48–72 hours are most effective in the treatment of chronic osteomyelitis. This therapy requires a commitment from the patient, the operative house staff, and the orthopaedic surgeon to ensure that the potential for recurrence is eliminated. Results have been excellent when the difficult problem of chronic osteomyelitis has been approached in this manner.

References

- Abbott LC, Schottstaedt ER, Saunders JB, et al: The evaluation of cortical and cancellous bone as grafting material. *J Bone Joint Surg* 29:381, 1947.
- Anderson LD, Horn LG: Irrigation-suction technique in the treatment of acute hematogenous osteomyelitis, chronic osteomyelitis, and acute and chronic joint infections. *South J Med* 63:745, 1970.
- Bansal VP, Harmit S: Management of chronic osteomyelitis using an irrigation suction technique. *Int Orthop* 12:265, 1988.
- Bickel WH, Bateman JG, Johnson WE: Treatment of chronic hematogenous osteomyelitis by means of saucerization and bone grafting. *Surg Gynecol Obstet* 96:265, 1953.
- Bingham R: The therapeutic effect of cold in bone and joint infection: Part I. *Am J Orthop Surg* June, 138, 1968.
- Bingham R: The therapeutic effect of cold in bone and joint infection: Conclusion. *Am J Orthop Surg* July, 186, 1968.
- Brand RA, Black H: Pseudomonas osteomyelitis following puncture wounds in children. *J Bone Joint Surg* 56A:1637, 1974.
- Bryson AF, Mandell DB: Primary closure after operative treatment of gross chronic osteomyelitis: A preliminary report. *Arch Surg* 51:81, 1945.
- Buchman J: The rationale and results of maggot therapy in chronic osteomyelitis. *NY State J Med* August 15, 1540, 1939.
- Buchman J, Blair JE: Penicillin in the treatment of chronic osteomyelitis. A preliminary report. *Arch Surg* 51:81, 1945.
- Cicszynski T: Stimulation and suppression of bone regeneration by electric polarization in humans. *Calcif Tissue Res* 4(Suppl.):134, 1970.
- Clawson DK, Dunn AW: Management of common bacterial infections of bones and joints. *J Bone Joint Surg* 49A:164, 1967.
- Clawson DK, Stevenson JK: Treatment of chronic osteomyelitis. *Surg Gynecol Obstet* 120:59, 1965.
- Coleman HM, Bateman JE, Dale GM, et al: Cancellous bone grafts for infected bone defects. *Surg Gynecol Obstet* 83:392, 1946.
- Compere EL: Treatment of osteomyelitis and infected wounds by closed irrigation with a detergent-antibiotic solution. *Acta Orthop Scand* 32:324, 1962.
- Compere EL, Metzger WI, Mitra RN: The treatment of pyogenic bone and joint infections by closed irrigation (circulation) with a non-toxic detergent and one or more antibiotics. *J Bone Joint Surg* 49A:614, 1967.
- De Oliveira JC: Bone grafts and chronic osteomyelitis. *J Bone Joint Surg* 53:157, 1975.
- Dombrowski ET, Dunn AW: Treatment of osteomyelitis by debridement and closed wound irrigation-suction. *Clin Orthop* 43:215, 1965.
- Eckardt JJ, Grogan TJ: Giant cell tumor of bone. *Clin Orthop* 204:45, 1986.
- Esterhai JL, Pisarello J, Brighton CT, et al: Treatment of chronic refractory osteomyelitis with adjunctive hyperbaric oxygen. *Orthop Rev* 27:809, 1988.
- Evans EM, Davies DM: The treatment of chronic osteomyelitis by saucerization and secondary skin grafting. *J Bone Joint Surg* 51B:454, 1969.
- Farrow RC: Summary of results of bone grafting for war injuries. *J Bone Joint Surg* 30A:31, 1948.
- Fitzgerald RH, Brewer NS, Dahlin DC: Squamous-cell carcinoma complicating chronic osteomyelitis. *J Bone Joint Surg* 58A:1146, 1976.
- Fitzgerald RH, Landells DG, Cowan JDE: Osteomyelitis in children: Comparison of hematogenous and secondary osteomyelitis. *Can Med Assoc J* 112:166, 1975.
- Fitzgerald RH, Ruttle PE, Arnold PG, et al: Local muscle flaps in the treatment of chronic osteomyelitis. *J Bone Joint Surg* 67A:181, 1984.
- Gentry LO: Osteomyelitis: Options for diagnosis and management. *J Antimicrob Chemother* 21(Suppl. C):115, 1988.
- Goel MK, Agarwal AK: Pyogenic bone joint infection: Treatment with closed irrigation and suction. *Ind J Med Sci* 29:263, 1975.
- Green SA, Ripley MJ: Chronic osteomyelitis in pin tracks. *J Bone Joint Surg* 66A:1092, 1984.
- Hall BB, Fitzgerald RH, Rosenblatt JE: Anaerobic osteomyelitis. *J Bone Joint Surg* 65A:30, 1983.
- Hazlett JW: The use of cancellous bone grafts in the treatment of subacute and chronic osteomyelitis. *J Bone Joint Surg* 36B:584, 1954.
- Hedstrom SA: The prognosis of chronic staphylococcal osteomyelitis after long-term antibiotic treatment. *Scand J Infect Dis* 6:33, 1974.
- Hogeman KE: Treatment of infected bone defects with cancellous bone-chip grafts. *Acta Chir Scand* 98:576, 1949.
- Horwitz T: Surgical treatment of chronic osteomyelitis complicating fractures. A study of 50 patients. *Clin Orthop* 96:118, 1973.
- Kelly PJ: Osteomyelitis in the adult. *Orthop Clin North Am* 6:983, 1975.
- Kelly PJ, Martin WJ, Coventry MB: Chronic osteomyelitis. 2. Treatment with closed irrigation and suction. *JAMA* 213:1843, 1970.
- Kelly RP, Rosati LM, Murray RA: Traumatic osteomyelitis: The use of skin grafts—Part I. *Ann Surg* 122:1, 1945.
- Kelly RP, Rosati LM, Murray RA: Traumatic osteomyelitis: The use of skin grafts—Part II. *Ann Surg* 123:688, 1946.
- Key JA: Amputation for chronic osteomyelitis. *J Bone Joint Surg* 26:350, 1944.
- Knight MP, Wood GO: Surgical obliteration of bone cavities following traumatic osteomyelitis. *J Bone Joint Surg* 27:547, 1945.

40. Le Frock JL, Rolston KVI, Molavi A: Management of osteomyelitis and soft-tissue infections. *Del Med J* 56:289, 1984.
41. Mathes SS, Alpert BS, Chang N: Use of muscle flap in chronic osteomyelitis: Experimental and clinical correlation. *Plast Reconstr Surg* 69:815, 1982.
42. Medoff G: Current concepts in the treatment of osteomyelitis. *Postgrad Med* 58:157, 1975.
43. Mowlem R: Cancellous chip bone-grafts. Reports on 75 cases. *Lancet* 2:746, 1944.
44. Orr HW: The treatment of osteomyelitis and other infected wounds by drainage and rest. *Surg Gynecol Obstet* 45:446, 1927.
45. Prigge EK: The treatment of chronic osteomyelitis; by the use of muscle transplant or iliac graft. *J Bone Joint Surg* 28:576, 1946.
46. Rowling DE: The positive approach to chronic osteomyelitis. *J Bone Joint Surg* 41B:681, 1959.
47. Taylor AR, Maudsley RH: Instillation-suction technique in chronic osteomyelitis. *J Bone Joint Surg* 52B:88, 1970.
48. Touhey JE, Davis JC, Workman WT: Hyperbaric oxygen therapy. *Orthop Rev* 26:41, 1987.
49. Waldvogel FA, Vasey H: Osteomyelitis: The past decade. *N Engl J Med* 303:360, 1980.
50. Weiland AJ, Moore JR, Daniel RK: The efficacy of free tissue transfer in the treatment of osteomyelitis. *J Bone Joint Surg* 66A:181, 1984.
51. Eckardt JJ, Wirganowicz PZ, Mar T: An aggressive surgical approach to the treatment of chronic osteomyelitis. *Clin Orthop* 298:229-239, 1994.
52. Ziment I, Miller LG, Finegold SM: Nonsporulating anaerobic bacteria in osteomyelitis. *Antimicrob Agents Chemother* 7:77, 1967.