

Chronic Instability of the Distal Radioulnar Joint: A Review

STEFAN FORNALSKI, B.S., THAY Q. LEE, PH.D., AND RANJAN GUPTA, M.D.

Introduction

Although our understanding of human anatomy has grown rapidly, the distal radioulnar joint (DRUJ) remains one of the least understood joints in the body. Problems of the DRUJ have been called by Palmer as the “low back pain of the wrist” [29]. Darrach’s description in 1912 of a chronic DRUJ dislocation and its treatment with an ulnar head resection is one of the earliest reports about the DRUJ [9]. Over the last 15 years, there has been a tremendous surge in research involving the anatomy, function, and treatment of DRUJ pathology. Yet, there is still no consensus as to the pathomechanics and the treatment of DRUJ pathology.

Evolution of the wrist began some 400 million years ago with the pectoral fins in a primitive fish known as the *Crossopterygia*. Several hundred million years later, the primitive amphibian, *Eryops*, appeared with a pentadactyl extremity, thirteen carpal bones, and a syndesmotic DRUJ. Prono-supination was not present in the *Eryops* as the ulna was the primary weight-bearing bone of the forearm. From the amphibian to the reptile, the anatomy of the upper extremity remained relatively unchanged. It was not until mammals first appeared about 230 million years ago that the forearm began to change significantly. With continued internal rotation and pronation of the forearm, the mammal was able to place its extremity in a more efficient position under its body. With the development of bipedalism, *hominids* developed a mobile wrist which was important for brachiation, food gathering, self-protection, and care of their young. Complex motion including supination and pronation developed with the evolution of three distinct characteristics 1) proximal retreat of the ulna so that there was no bony articulation between the ulna and carpus, 2) development of the triangular fibrocartilage complex (TFCC) and ulnocarpal meniscus, and 3) the development of the DRUJ into a synovial joint [4,22].

Anatomy and Function

A proper understanding of the complex anatomy of the DRUJ is crucial for the surgeon in order to both properly diagnose and treat patients with chronic DRUJ instability. The DRUJ is part of an interconnected forearm unit. Supi-

nation and pronation occur through a complex interaction of bony articulations and soft tissue structures including the radiocapitellar joint, the proximal radioulnar joint (PRUJ), the interosseous membrane (IOM), and the DRUJ. Forearm rotation occurs around a longitudinal axis that extends proximally from the radial head through the head of the ulna distally [16,42]. Forearm rotation range of motion normally averages 150 degrees. The DRUJ must allow for both significant mobility and still provide the structural support necessary for the transmission of force across the wrist and elbow. Eighty percent of force transmission across the wrist occurs through the radiocarpal joint and the remaining 20% through the ulnocarpal joint [32].

The shallow concave sigmoid notch of the distal radius articulates with the convex asymmetric shaped ulnar head (Fig. 1). The shallow sigmoid notch has a variable depth and is a triangular facet with three margins: dorsal, palmar, and distal (carpal) margins with average dimensions of 1.5 cm dorsovolar and 1 cm proximal-distal [17]. In a study involving 50 cadaver wrists, Tolat et al. demonstrated 4 main types of notch shapes in the transverse plane: 1) flat (42%), 2) ski-slope (14%), 3) hemicylindric (30%), 4) S-shaped (14%). The authors also reported a palmar osteocartilagenous lip in 80% of the specimens which acted as a stable buttress to palmar dislocation of the ulna [40].

The articulation of the sigmoid notch with the ulnar head allows rotation of the radiocarpal unit in the transverse plane. For this reason the head of the ulna has also become known as the “articular seat” (Fig. 1) [17]. The medial area of the ulna head has a bony prominence which is known as the ulnar styloid process. This is the point of attachment for soft tissue structures. The dorsal nonarticular portion of the ulna head has an osseous groove to accommodate the extensor carpi ulnaris tendon (ECU) [15]. Articular cartilage covers a 90 to 135 degree arc of the ulnar head, and only a 47 to 80 degree arc on the sigmoid notch. One important geometric joint characteristic of the DRUJ is the radius of curvature between the two articulating surfaces. The radius of curvature of the ulnar head (averages 10 mm) is different than the radius of curvature of the sigmoid notch (averages 15 mm). Consequently, pronation/supination consists of both a rotational component (transverse plane) and a sliding/translational component (anteroposterior plane) [13,17]. With the DRUJ in a neutral position, and the normal soft tissue support system intact, there exists a 2.8 mm dorsal and 5.4 mm palmar translation secondary to the differing radii of curvatures [17]. Joint surface contact is maximal

From the University of California, Irvine, Department of Orthopaedic Surgery, Irvine, CA 92697.

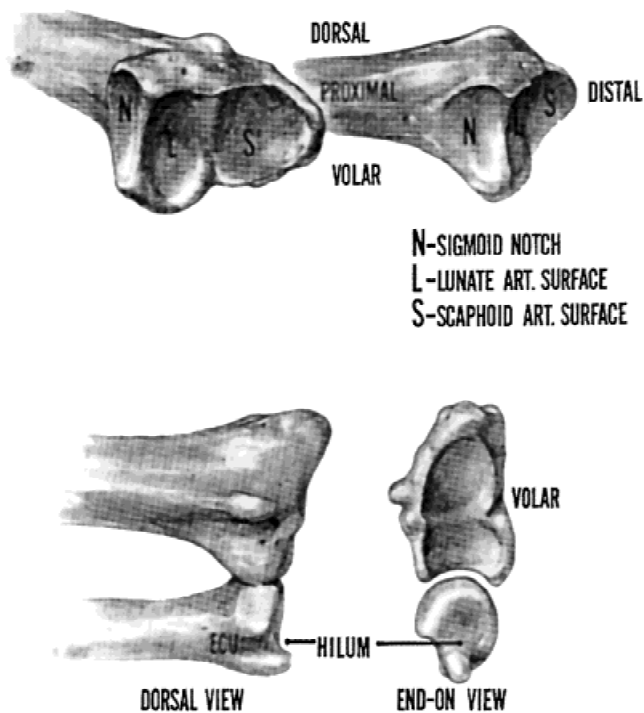


Fig. 1. (Above) Distal radius articulates with the ulnar head at the sigmoid notch and with the carpus at scaphoid and lunate fossae. (Below) Dorsal and coronal views of the radio-ulnar joint in neutral rotation. Note the groove for the extensor carpi ulnaris (ECU) on dorsal view and the differing radii of curvatures between the sigmoid notch and ulnar head seen on coronal view [17]. (Reprinted with permission from Churchill Livingstone, Harcourt International.)

(60%) at neutral position and minimal ($\leq 10\%$) in full supination or pronation [13]. In the frontal plane, the two articular surfaces are usually not parallel as the mean inclination of the sigmoid notch is 7.7 degrees from the longitudinal axis of the radius while the mean articular seat of the ulnar head, 21 degrees [37]. These anatomic characteristics of the DRUJ make the joint inherently unstable. As such, the soft tissue support system around the DRUJ must act as crucial stabilizers.

The soft tissue support system of the DRUJ can be divided into static and dynamic stabilizers. Static stabilizers include the triangular fibrocartilage (TFC), ulnocarpal ligaments, and the interosseous membrane (IOM) (Fig. 2) [15]. The TFC and ulnocarpal ligaments are believed to be the key elements of an extensive fibrous system that arises from the carpal margin of the sigmoid notch of the radius, cups the lunate and triquetral bone, and reaches the volar base of the fifth metacarpal [40]. This complex has been termed the triangular fibrocartilage complex (TFCC) by Palmer and Werner [31]. The TFCC plays a role by 1) providing a flexible yet stable mechanism for rotation of the radiocarpal unit around the ulnar axis, 2) suspending the ulnar carpus from the ulnar side of the wrist, 3) cushioning forces transmitted through the ulnocarpal axis, 4) connecting the ulnar axis to the volar carpus, and 5) providing a continuous gliding surface across the distal face of the two forearm bones for carpal movement [17].

The TFC (different from the TFCC) is triangular in shape

and composed of both a peripheral and central component [17]. The palmar and dorsal radioulnar ligaments along the peripheral margins of the TFC are strong collagen structures which function under tensile loading [38]. This peripheral component attaches from the palmar and dorsal portions of the sigmoid notch of the radius (1–2 mm in thickness) to the ulna head and styloid process (5 mm in thickness). The central fibrocartilage component, also known as the articular disc, is believed to function in supporting compressive loads at the DRUJ. The second key elements of the TFCC are the ulnolunate and ulnotriquetral ligaments (ulnocarpal ligaments). These ligaments produce a “V” shape with the apex originating at the base of the styloid, at the point of TFC insertion, and continue distally to insert volarly on the triquetrum and lunate. The ulnocarpal ligaments resist dorsal displacement of the distal ulna relative to the carpus and radiocarpal unit. Thus, there are three main points of attachment for the TFC: the sigmoid notch, the ulnar styloid, and the volar ulnar carpus. As the ulnar styloid is a central insertion point for this fibrous support system, fractures about the base of the ulna styloid are important to repair [17,43].

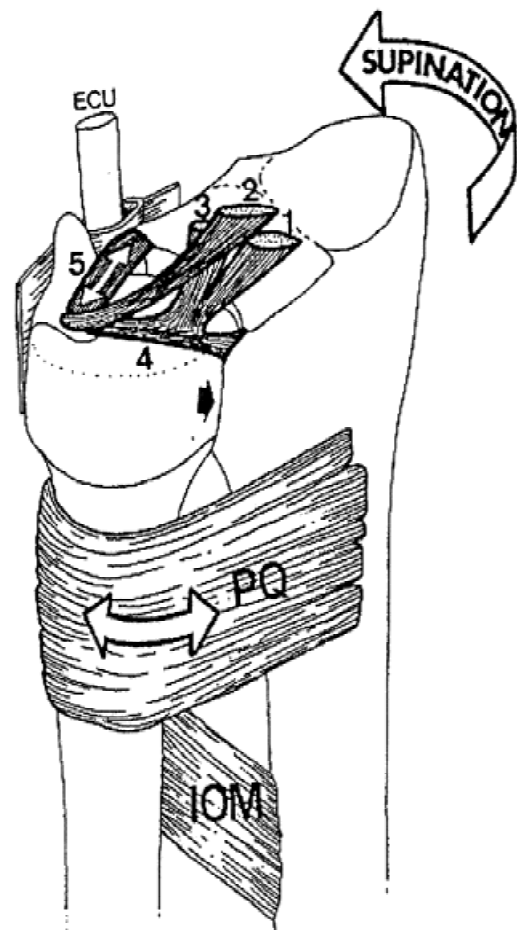


Fig. 2. Volar view of the distal radio-ulnar joint in full supination showing stabilizing structures. 1–3 = ulnocarpal ligaments, 4 = palmar radioulnar ligament, 5 = dorsal radioulnar ligament, ECU = extensor carpi ulnaris and ECU sheath, PQ = pronator quadratus, IOM = interosseous membrane, black arrow = coaptation of ulnar head against sigmoid notch of radius [15]. (Reprinted with permission from W.B. Saunders.)

The palmar and dorsal radioulnar ligaments of the TFC provide stability to the DRUJ at the extremes of supination and pronation. A number of investigators have studied this stability with apparently contradictory results. Af-Ekenstam [3] and Hagert [18] found the dorsal radioulnar ligament to be the major stabilizer during maximal supination by preventing volar ulna subluxation. They also reported that the palmar radioulnar ligaments resisted dorsal ulna subluxation during full pronation [3,18]. In contrast, studies by Schuind et al. [38], Adams and Holley [2], and Kihara et al. [19] suggest that the dorsal radioulnar ligament is most taut during maximum pronation and the palmar radioulnar ligament is most taut during supination.

The radio-ulnar interosseous membrane (IOM) is a static stabilizer that plays an important role in force transmission through the forearm and as a tether between the radius and ulna. The IOM is most taut during supination and prevents diastasis between the radius and ulna [16]. The pronator quadratus muscle attaches distally to both the radius and ulna. It functions as a static stabilizer by maintaining coaptation of the ulnar head in the sigmoid notch passively by its viscoelastic constraints during supination [17].

The dynamic stabilizers of the DRUJ are the extensor carpi ulnaris muscle (ECU)/infratendinous extensor retinaculum and the pronator quadratus muscle. Distally the tendon of the ECU crosses the dorsal ulnar head through an osseous groove and is kept in place by the infratendinous extensor retinaculum. This system resists dorsal ulna dislocation with full pronation, and palmar ulna displacement with full supination [15]. The pronator quadratus, in addition to functioning as a static stabilizer, also acts as a dynamic stabilizer. With contraction, it actively maintains coaptation of the ulnar head in the sigmoid notch during pronation [17].

Pathogenesis of Chronic DRUJ Disorders

Chronic instability about the DRUJ can be a challenging problem for the clinician. In order to determine the proper treatment, the specific pathology must be identified. Chronic DRUJ instability can be due to a bony deformity, a ligamentous injury, or a combination of both. The direction of instability of the ulna relative to the radiocarpal unit may be volar, dorsal, or both (most commonly dorsal). Acute injuries that are not diagnosed or treated properly can become chronic DRUJ problems. Instability about the DRUJ is a complex topic, but can be thought of in simplified terms. Stability is normally provided by 1) the somewhat unique articulation between the ulnar head and sigmoid notch, 2) the alignment and length between the radius and ulna, 3) the TFCC, and 4) the adjacent supporting structures such as the ECU, IOM, and pronator quadratus. Stability may be lost with disruption of joint architecture due to 1) fractures/malunions/nonunions of the sigmoid notch, distal radius, ulnar head, and ulnar styloid process, 2) alteration of the length relationships between the radius or ulna or diaphyseal angulation/rotational malunions of the forearm bones, and 3) chronic ligament insufficiency [7,17,20]. One

of the most common causes of distal radio-ulnar incongruity is a malunion of a prior distal radius fracture [35].

Palmer and Werner classified specific TFCC injury patterns [30,31]. These can be found summarized in Table 1. The authors classified TFCC injuries as either traumatic (class 1) or degenerative (class 2). Traumatic TFCC lesions most likely result from a fall on an outstretched upper extremity or from a hypersupination/pronation of the forearm. Degenerative lesions of the TFCC most likely result from repetitive loading of the TFCC [30]. In addition, it has been shown that the majority of individuals over age 50 have degenerative TFCC lesions. The pathomechanics of rheumatoid arthritis is also an etiology of degeneration of the TFCC [24,43]. Melone et al described TFCC disruption as a spectrum of injury resulting in five stages of increasing severity [23]. Bowers and Zelouf classified chronic DRUJ disorders by chronic joint disruption due to TFC tears with and without bony malunion involvement; ulnocarpal impingement; and in arthritic joints [20]. This classification can be found in Table 2. The reader is encouraged to refer back to Table 2 throughout this article including when reading the surgical treatment section.

Diagnosis

Disorders of the DRUJ can represent a diagnostic challenge to the clinician not only due to the pathology but also due to the large number of ancillary studies available. A thorough medical history and physical examination of the involved upper extremity are always of importance. The history should include the patient’s age, hand dominance, occupation, previous injury/problems/surgery, position reproducing pain, history of rheumatoid or osteoarthritis, and detailed symptom characteristics. With chronic instability, patients may complain of ulnar sided wrist pain, weakness

Table 1. Triangular fibrocartilage complex (TFCC) abnormalities

Class I—Traumatic
A. Central perforation
B. Ulnar avulsion with distal ulnar fracture without distal ulnar fracture
C. Distal avulsion
D. Radial avulsion with sigmoid notch fracture without sigmoid notch fracture
Class 2—Degenerative (Ulnocarpal abutment syndrome)
Stage:
A. TFCC wear
B. TFCC wear
+ lunate and/or ulnar chondromalacia
C. TFCC perforation
+ lunate and/or ulnar chondromalacia
D. TFCC perforation
+ lunate and/or ulnar chondromalacia
+ L-T ligament perforation
E. TFCC perforation
+ lunate and/or ulnar chondromalacia
+ L-T ligament perforation
+ ulnocarpal arthritis

L-T, Lunotriquetral

in grip strength, redness and swelling at the DRUJ, “giving way” or a “clunk” in the wrist, and deformity of the dorsal portion of the wrist (dorsal ulna head subluxation) [7,17,20].

Physical examination should always include the unaffected side for comparison. Physical examination is begun with an evaluation of both wrists for any gross abnormalities, deformities, swelling, or redness. A subluxing ulnar head may be prominent dorsally on the wrist or the caput ulnar syndrome may be present. Active wrist motion usually reveals a limitation in the range of motion secondary to pain or altered biomechanics. The patient is asked to position the wrist to reproduce the pain. At the same time, the examiner should listen for a “clunk”. Grip and pinch strength should be tested bilaterally. The “piano key test” can be performed with the hand pronated and the examiner “ballotting” the dorsal ulna head. A positive “piano key test” occurs when there is very little resistance to ballotment and volar movement of the ulna head [20]. In addition, the DRUJ can be “shucked”, to identify joint laxity and crepitus, by holding the radius in one hand and the ulna with the other and moving the distal radius in a volar/dorsal direction. The

Table 2. Chronic distal radioulnar joint problems and the procedures available for their treatment

I. Chronic joint disruption (potential, intermittent or continuous instability)
A. Central TFC tears (potential instability—Herbert-Bowers stage I)
1. Arthroscopic debridement
2. Open repair and debridement
B. Joint disruption due to chronic ligament or bony injury (Herbert-Bowers Stage II [dynamic] or III [static-reducible] instability)
1. TFC peripheral tears
a. Repair and/or reattachment
b. Substitution
2. TFC peripheral tears plus radial and/or ulnar angular shaft deformity
a. Radial osteotomy
b. Ulnar osteotomy
3. Sigmoid notch and/or ulnar head deformity
a. Corrective osteotomy
b. Arthroplasty
II. Ulnocarpal impingement (impaction, abutment)
A. Immature skeleton—growth arrest
B. Adult skeleton
1. Shortening intrinsic to joint (“wafer” procedure)
2. Ulnar shaft shortening (Milch type)
III. Procedures to address the arthritic joint
A. Arthroplasty
1. Partial resections (Bowers, Watson procedures)
2. Complete resections (Darrach procedure and its modifications)
3. Joint replacement
B. Arthrodesis
C. Arthrodesis with surgical pseudarthrosis of ulna (Sauve-Kapandji procedure)
IV. Other procedures
A. Restoring the chronically unstable extensor carpi ulnaris
B. Relieving rotational contracture

ECU tendon/sixth extensor compartment should be palpated and evaluated during resisted pronation to identify any subluxation [12,20]. Finally, the exam is completed with a sensory, motor, and vascular assessment of the entire upper extremity [35].

Imaging techniques available to evaluate the DRUJ include plain radiographic films, computed tomography (CT) with or without digital reconstruction, magnetic resonance imaging (MRI), wrist arthrography, bone scans, and wrist arthroscopy [17]. Posterioranterior, lateral, ulnar deviation, radial deviation views at zero rotation and posterioranterior and lateral views in full pronation and supination should be taken. Forearm rotation on these views can be assessed by comparison of the ulnar styloid to the shaft of the ulna and radius and can also determine carpal deviation by comparing the position of the lunate with the position of the radius (Fig. 3) [12,17]. These plain films can be compared to the contralateral side for radioulnar widening, ulnar variance, ulnar dislocation, carpal height, lunate position, scapholunate angle, and intercarpal distance [12]. Although ulnar variance is the comparison of the length of the ulna relative to the radius, ulnar variance differs among individuals and must always be compared to the contralateral wrist [12]. Palmer and Werner have shown that the force distributed across the TFCC changes dramatically from 5% to 40% when the ulnar variance changes from -2 mm to $+2.5$ mm [29,31]. Ulnar variance has been associated with arthrosis, Kienbock’s disease, and ulnar impaction syndrome [12].

Advanced imaging techniques such as CT, MRI, and wrist arthrography may offer additional information about the etiology of chronic DRUJ instability. With CT scans, evaluation of DRUJ subluxation/dislocation, fractures, sigmoid notch abnormalities may be performed. Digital reconstruction of CT scans is especially useful to construct a picture of the DRUJ in any desired plane after supination, pronation, and neutral views are obtained [17]. With MRI scans, soft tissue abnormalities including TFCC pathology may be evaluated [34,36]. Potter et al showed in a prospective study of 77 patients that MRI had 100% sensitivity, 90% specificity, and an accuracy of 97% for detecting TFCC tears [34]. Such high caliber MRI may not always be available to clinicians. Therefore, MRI utilization should be limited to suspicion of Kienbock’s disease, an occult ganglion cyst, or a tumor. Wrist arthrography is another means of identifying perforations of the TFCC, and scapholunate and lunotriquetral interosseous ligaments. The arthrogram is often the next step if plain films show no abnormalities. The three compartment technique has been shown to be the most sensitive wrist arthrogram technique in identifying ligament pathology by allowing evaluation of the radioulnar, midcarpal, and radiocarpal joints [20]. Bone scans normally are not a first line of imaging with ulnar sided wrist pain, but may be helpful with identifying pathologic lesions in the patient with unclear wrist pain and normal radiographs. Bone scans of the wrist and hand may be used to rule out osteomyelitis, occult fractures, and sympathetic dystrophy [20].

Wrist arthroscopy is quickly evolving as the definitive choice for both evaluation and treatment of chronic DRUJ instability. It allows the surgeon to directly visualize the

TFCC, the radiocarpal ligaments, and the articular cartilage with a much smaller incision than the open technique. Osterman reported that with arthroscopic debridement of TFCC tears 73% of 52 patients had full resolution of ulnar wrist pain and an additional 12% had significant improvement of their symptoms. These patients were also reported to have less bleeding, less pain, and a faster return to normal range of motion and strength as compared to patients with an open excision [27,28]. A lesion seen on diagnostic imaging studies may or may not be symptomatic. To obtain a complete picture, imaging data must always be considered along with the patient history and physical exam.

Surgical Treatment of Chronic DRUJ Instability Without Arthritis

An unstable DRUJ without arthritis may be stabilized with the repair of the TFCC and/or with the correction of bony malunions. If successful, this anatomic intra-articular reconstruction may restore stability with minimal loss of motion. If the TFCC is not repairable or the repair is un-

successful as demonstrated by continued instability, pain, and decreased range of motion, an extra-articular reconstructive approach may be warranted. Although a variety of extra-articular soft tissue reconstructions exist, they are all contraindicated if arthritic changes are present. In addition, bony malunions and length discrepancies must be corrected before or at the time of soft tissue reconstruction [1,17,20]. These general concepts of reconstruction re-create some of the stabilizing elements of the TFCC with tenodesis of the distal ulna using the ECU or flexor carpi ulnaris (FCU) tendon; creating an ulnocarpal tether; and/or creating a radioulnar tether [1].

A commonly utilized soft tissue reconstruction is the combined ECU/FCU tenodesis described by Breen and Jupiter (Fig. 4) [8]. This technique involves both a dorsal and palmar approach. A dorsal incision is made from the carpus to 10 cm proximal over the distal ulna. The extensor retinaculum is divided longitudinally, mobilized, and constructed into a circular pulley for dorsal ECU stabilization. Next the distal ulna is resected extraperiosteally just proxi-

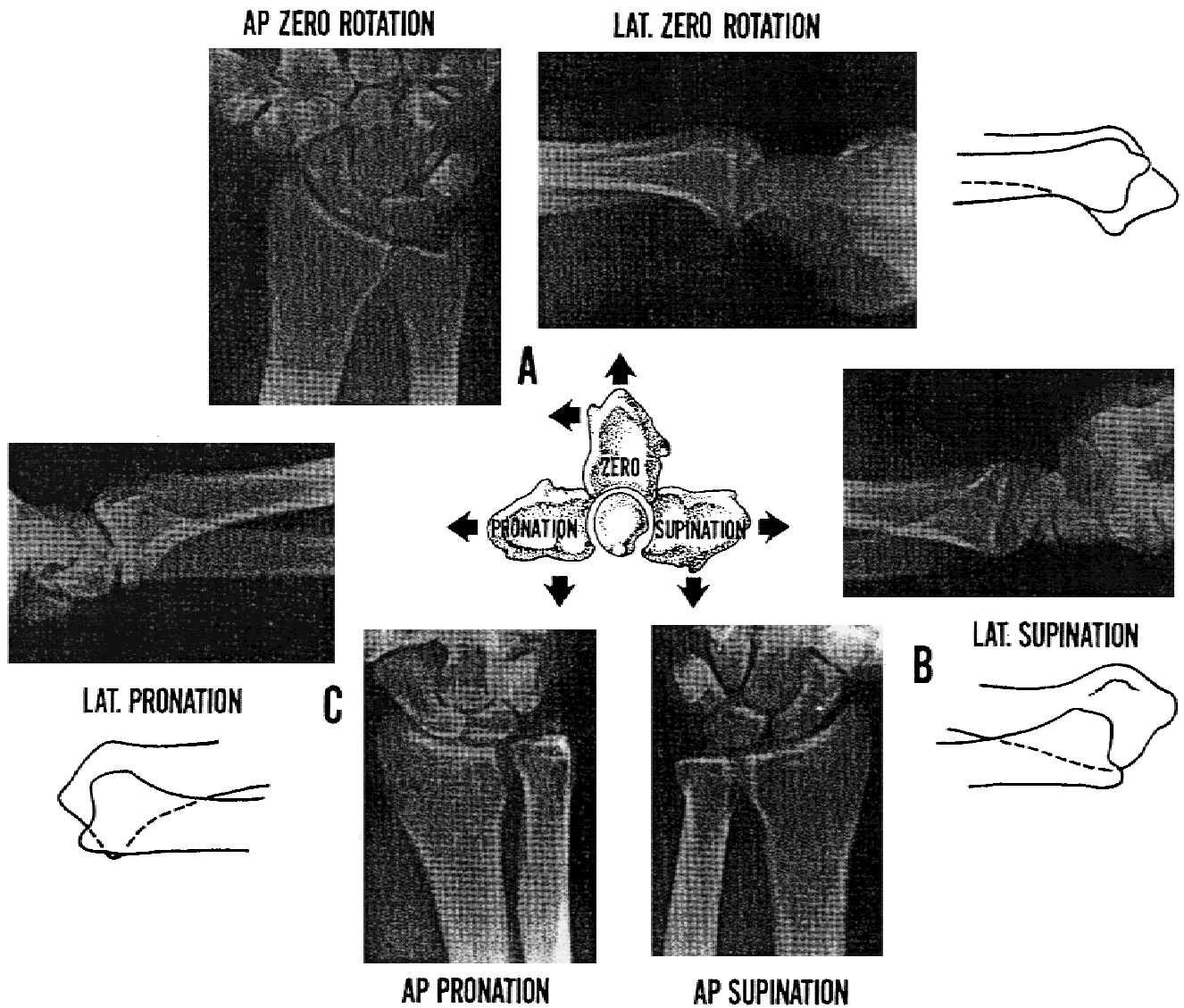


Fig. 3. Standard radiographic views used in evaluation of the distal radio-ulnar joint. Forearm rotation in zero rotation, full pronation, and full supination [17]. (Reprinted with permission from Churchill Livingstone, Harcourt International.)

mal to the sigmoid notch. Then a 9–10 cm proximal based slip of ECU tendon is created. Through a palmar approach, a 8–10 cm distally based slip of FCU tendon (still attached to the pisiform) is constructed and passed dorsally at the level of the distal ulna. A 1/4-inch drill is used to create a communicating perpendicular and longitudinal hole in the distal ulna. A tenodesis weave is then created by passing both the ECU and FCU tendon slips through these drill holes and suturing them to one another. The ECU is then dorsally stabilized with the circular pulley constructed from the extensor retinaculum [8].

The Bunnell-Boyes reconstruction addresses DRUJ instability by re-creating the stabilizing force of the ulnocarpal ligaments (Fig. 5) [17]. A portion of the FCU insertion is harvested proximally and stripped distally to the insertion on the pisiform. Next the distal portion of the harvested ligament is stabilized by weaving it through the volar capsule to relieve possible torque experienced by the pisotriquetral joint. The proximal portion of the harvested ligament is passed through a drill hole in the ulna close to the styloid and sutured to itself. Finally the repair is completed with imbrication of the dorsal capsule [17,20]. Tsai and

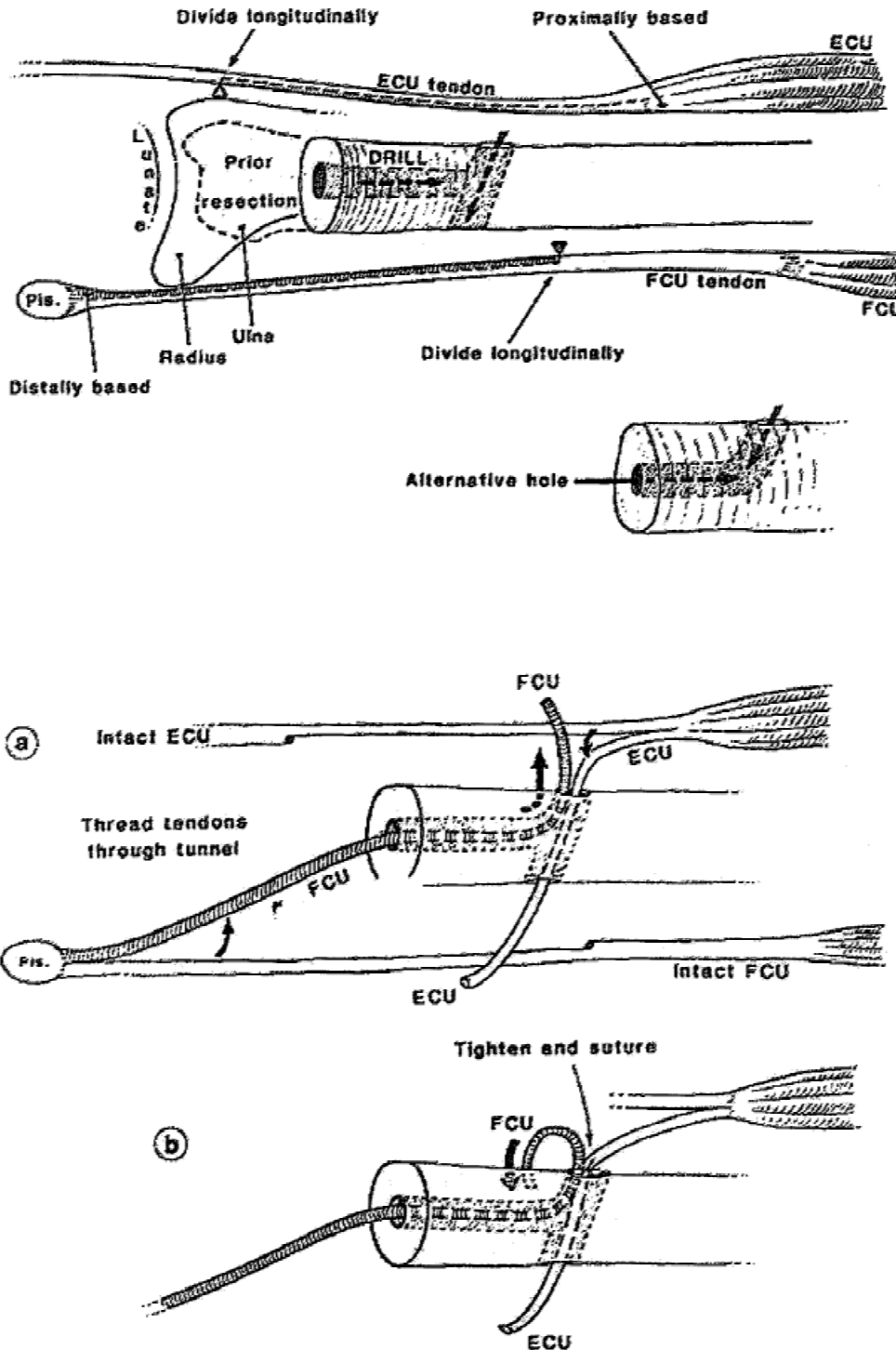


Fig. 4. ECU/FCU tenodesis as described by Breen and Jupiter. (Above) Creation of the ECU slip. (Below) Figure A shows passage of the ECU through the drill holes and Figure B shows start of the tenodesis weave [8]. (Reprinted with permission from W.B. Saunders.)

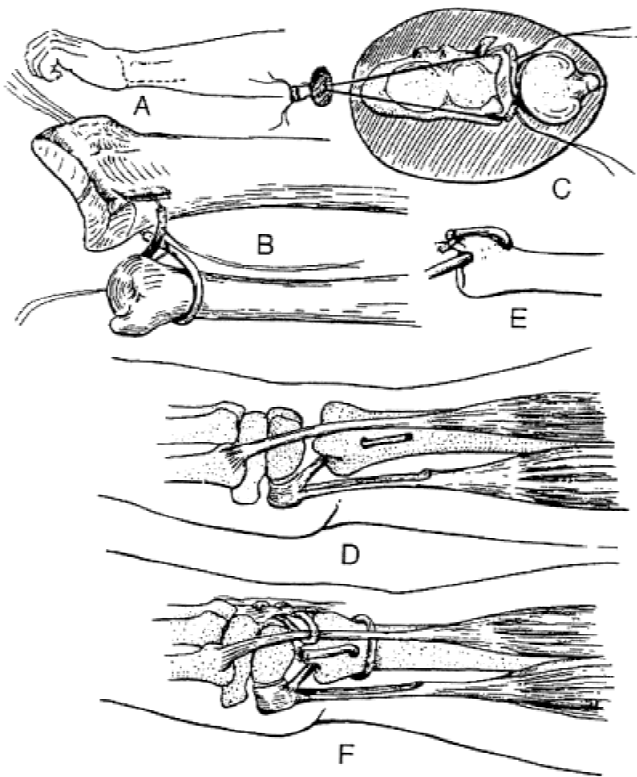


Fig. 5. Bunnell/Boyes reconstruction of the distal radio-ulnar joint [17]. (Reprinted with permission from Churchill Livingstone, Harcourt International.)

Stillwell have utilized this concept for stabilization of the ulnar stump after the Darrach procedure (Fig. 6) [11,17,20].

Johnson proposed advancement of the pronator quadratus to decrease dorsal instability of the distal ulna. The pronator quadratus normally attaches to both the distal radius and ulna. With this method, the pronator quadratus is advanced from its normal insertion point on the distal ulna to a more lateral and posterior insertion (Fig. 7) [17,20].

An osteotomy of the radius or ulna can be used to correct angular, rotational, or length discrepancies between the forearm bones. Frequently, the radius may be shortened after a distal radius fracture. In addition to correcting length, an osteotomy of the radius can be used to re-create volar tilt and ulnar inclination, and to correct malunions of the sigmoid notch. The technique usually requires the use of bone graft and rigid internal fixation [17,20].

Techniques for an ulnar osteotomy include: a transverse osteotomy which may be used for a shortening, a lengthening (bone graft needed), or a rotational correction. The step-wise and oblique techniques are normally only used for shortening. Rigid internal fixation is always necessary [17,20]. Ulnar impaction syndrome is chronic abutment of the ulnar head against both the carpal bones and TFCC and causes excessive load transmission across the ulnocarpal portion of the wrist [10,14,17]. Ultimately, this results in degenerative changes at the ulnar side of the wrist. Some of the more common causes of ulnar impaction syndrome are congenital positive ulnar variance, malunion of the distal radius, premature physal arrest, and previous radial head resection [10]. There are two common techniques used to

treat this pathology, the Milch procedure and the Wafer procedure. The Milch procedure and a number of modern variations of this technique resect a portion of the distal ulnar diaphysis and hold the osteotomy in place with internal fixation [14,17]. The Wafer procedure involves excision of a 2–4 mm wafer of cartilage and bone from the ulnar articular bone just below the TFC. This technique can correct a 2–4 mm positive variance while keeping the TFC and ulnocarpal ligaments intact. When compared to the Milch technique, two advantages of the Wafer technique are minimal disturbance of the distal radioulnar articulation and no internal fixation [17,23].

Surgical Treatment of Chronic DRUJ Instability with Arthritis

Arthritis at the DRUJ can be caused by osteoarthritis, rheumatoid arthritis, and early degenerative arthritis. With osteoarthritis, cartilage debris from wear and osteophyte formation may result in an articular incongruity [17]. With rheumatoid arthritis, DRUJ synovitis leads to DRUJ instability with the loss of cartilage and bone, weakening and

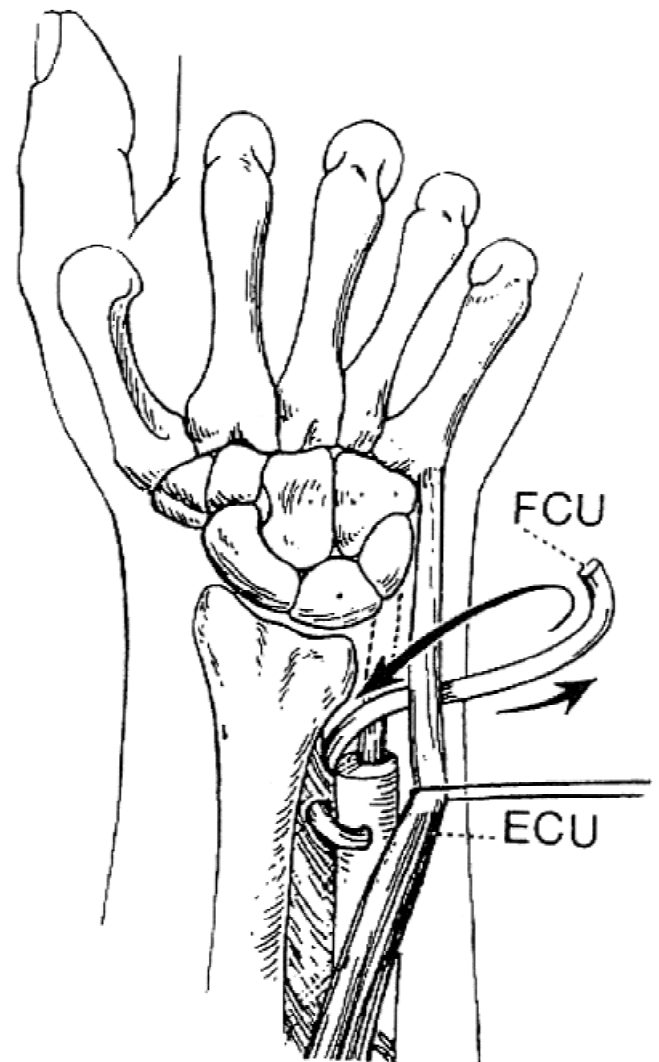


Fig. 6. A modified Darrach procedure using the flexor carpi ulnaris to stabilize the ulnar stump [17]. (Reprinted with permission from Churchill Livingstone, Harcourt International.)

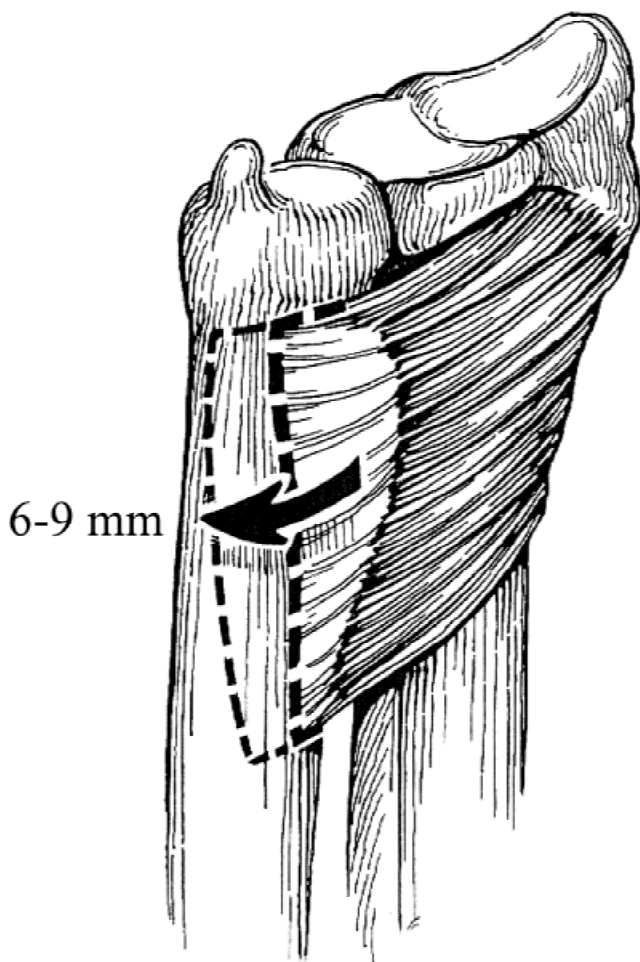


Fig. 7. Volar view of the distal radio-ulnar joint showing the pronator advancement technique described by Johnson [17]. (Reprinted with permission from Churchill Livingstone, Harcourt International.)

laxity of ligaments, and tendon rupture [26,39]. Using centre analysis with an *in vivo* study, Weiler et al. demonstrated that erosions of the sigmoid notch due to rheumatoid arthritis significantly alters the normal kinematics of the DRUJ [41]. Early degenerative arthritis may be caused by an ulnar impaction syndrome and/or an articular incongruity secondary to a bony malunion. A number of ablative surgical procedures exist for the treatment of DRUJ arthritis. They include the Darrach resection, the Hemiresection Interposition Arthroplasty, the Matched distal ulna resection, and the Sauve'-Kapandji procedure [11,17,21,25,26,39].

The classic Darrach resection consists of simple excision of the distal ulna and remains the standard ablative procedure to which all others are compared. It was introduced by William Darrach in 1912 for a patient with post-traumatic subluxation [17,21]. The ulna is approached through a medial based skin incision. Subperiosteal dissection of the most distal one inch of ulna is done between the FCU and ECU interval. An osteotomy is performed to remove the distal one inch of ulna, while leaving the ulnar styloid in place. The periosteal sleeve is repaired and the skin is closed. Darrach believed that the periosteal sleeve could function as a firm attachment point for the remaining styloid and ulnocarpal ligaments and possibly allow the ulna to

regenerate and adapt to the functional demands of the wrist [17,21]. The Darrach procedure is a destabilizing technique, with the TFCC and ECU uncoupled from the remaining proximal ulna [11,17,20,21,25,26,39]. Bieber et al. reported continued DRUJ instability even with the remaining periosteal sleeve [21]. Nevertheless, the Darrach remains a classic technique and has influenced a number of newer ablative procedures.

The Hemiresection Interposition Arthroplasty technique (HIT) was introduced by Bowers in 1984 [17,20,21]. This ablative procedure maintains an intact TFCC and reconstructs an incongruent DRUJ with autogenous tissue (Fig. 8). HIT is similar to Darrach in terms of resecting the ulna at the sigmoid notch and similar to Matched Distal Ulnar resection by retaining a portion of the distal ulna to maintain TFCC integrity [21]. HIT is unique as autogenous tissue is placed between the radius and ulna, and this in turn functions to prevent impingement [17,21]. The technique involves resection of the ulnar articular head, but maintains the shaft/styloid relationship. An autogenous piece of muscle, tendon, or capsule is placed in the DRUJ and functions to limit radial-ulnar abutment [17,20,21,26]. The advantage of this technique is a shorter recovery period as no bony union can occur and prolonged immobilization is not needed. The technique does require an intact or reconstructible TFCC [21].

In 1986, Watson introduced the Matched Distal Ulnar resection. Key components of this procedure are the elimi-

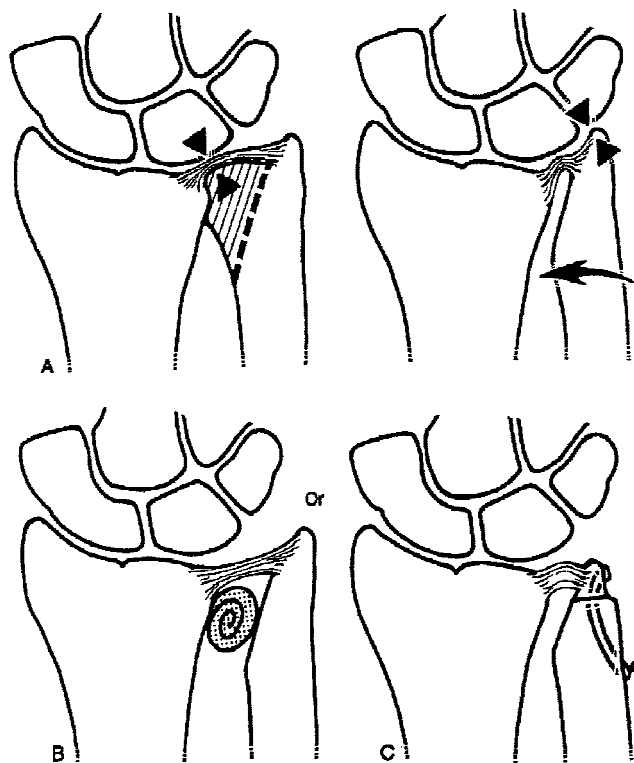


Fig. 8. The Bowers Hemiresection Interposition Arthroplasty Technique (HIT) Figure A and B show the resection and autogenous tissue placement between the radius and ulna. Figure C a modification to add an ulnar shortening to the procedure [17]. (Reprinted with permission from Churchill Livingstone, Harcourt International.)

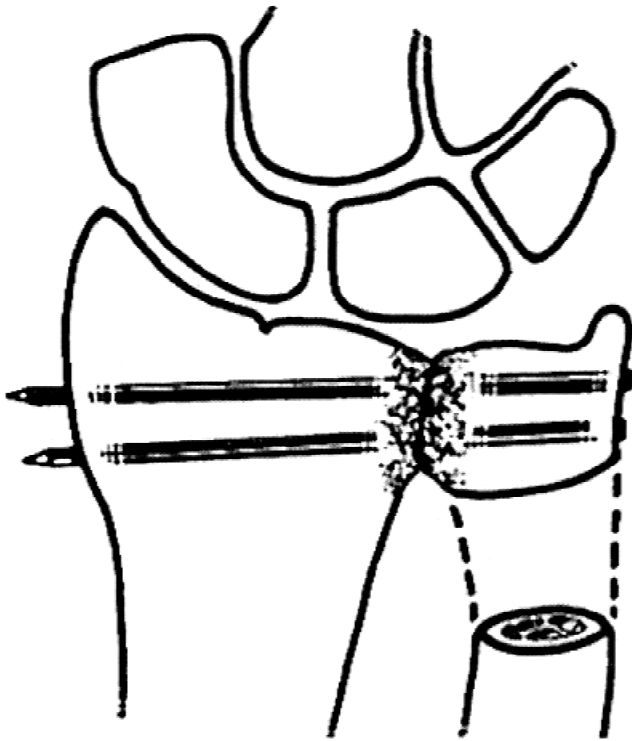


Fig. 9. The Sauve-Kapandji procedure [17]. (Reprinted with permission from Churchill Livingstone, Harcourt International.)

nation of the DRUJ articulation and maintenance of the TFCC. Watson reported that the ECU and other stabilizers adhere to the raw bone of the resected ulna and enhance stabilization. Rongeurs are used to resect 6 cm of the distal ulna, while maintaining a cuff of periosteum and ligamentous structures attached to the distal ulna. The ulna is resected and shaped into a long, sloping convex curve to match the opposing concave radius. In supination, direct visualization and palpation is used to assure adequate bone resection. In order to allow full pronation/supination, a 270 degree arc of ulna is ultimately resected [21].

In 1936, Sauve' and Kapandji introduced treatment of

DRUJ arthrosis by fusion of the distal radius and ulna and the creation of an ulna pseudoarthrosis proximal to this fusion (Fig. 9). With the ulnar head and neck exposed, 1.5–2.0 cm of the ulnar neck, just proximal to the ulnar head, is resected along with the periosteum. This leaves only the head and a small portion of the neck distally for radioulnar fusion. To expose subchondral cancellous bone for fusion, a rongeur is used to remove articular surfaces from both the ulnar head and sigmoid notch. Proper ulnar variance is verified radiographically. Permanent fixation is achieved by screw or Kirschner wire fixation across the distal radius and ulnar head. Fascia of the pronator quadratus is brought through the osteotomy site and sutured into the fascia over the proximal ulnar shaft. This interposition minimizes the risk of regrowth and fusion at the pseudoarthrosis. The IOM and TFCC are not disturbed [11,17,20,21]. The benefit of this procedure is that the radio-ulnar joint surface is maintained, and permits physiologic force transmission from the hand to the forearm [17,21].

Future Directions

Techniques of 3D motion analysis that have been successfully utilized in research involving the glenohumeral joint and cervical spine are now being employed to better understand the DRUJ. These include a magnetic tracking device, also known as the "Flock of Birds", the Polhemus system, and the Microscribe (3D digitizing system). Our own lab is currently utilizing a cadaveric model with the Microscribe to determine the effects of serial ligament transection on DRUJ kinematics and the contributions of TFCC structures to DRUJ stability (Fig. 10). Our model mimicks *in vivo* conditions by loading both the muscles producing pronation/supination and the dynamic stabilizers of the DRUJ with physiologic forces. In an unpublished study by Boler et al., a laboratory model has been utilized to test soft tissue reconstructions [6]. Petersen and Adams have also done biomechanical testing on a number of soft tissue reconstructions [33]. More extensive laboratory testing is nec-




Fig. 10. Experimental setup. (A) illustrates custom testing jig; (B) shows lateral view of experimental setup with specimen rigidly mounted in plaster of paris at both the humerus and the hand, the elbow fixed at 90 degrees flexion, and the forearm at neutral rotation. Microscribe is also present. (C) shows frontal view of testing jig.

essary and will be essential to understand both the functional anatomy and 3D kinematics of the DRUJ. An accurate laboratory model could allow *in vitro* (rather than empirical *in vivo*) comparison of both intra and extra-articular stabilization techniques. In addition, the kinematic and biomechanical changes associated with new stabilization techniques, such as thermal capsular shrinking of the DRUJ capsule and TFCC, can be evaluated with a reliable cadaveric model.

Conclusion

Because of its osseous geometry, the DRUJ is inherently an unstable joint. The soft tissues surrounding the DRUJ must contribute significantly to joint stability. A proper understanding of the complex anatomy and function of the DRUJ is essential for the treating clinician. Chronic instability of the DRUJ continues to challenge orthopedic surgeons. The definitive surgical treatment of DRUJ instability remains controversial. As there has been an increase in research relating to the DRUJ over the last 15 years, our understanding of the anatomy, biomechanics, and pathogenesis continues to improve. Because of the many remaining unanswered questions, research of the DRUJ is likely to continue for some time. An accurate laboratory model is a necessary tool to evaluate the biomechanical properties of the soft tissues. These future studies will also help surgeons to learn which stabilization techniques most accurately recreate normal DRUJ kinematics.

References

- Adams BD: Distal radioulnar joint instability. *Instr Course Lect* 47: 209–213, 1998.
- Adams BD, Holley KA: Strains in the articular disk of the triangular fibrocartilage complex: a biomechanical study. *J Hand Surg [Am]* 18:919–925, 1993.
- af Ekenstam F, Hagert CG: Anatomical studies on the geometry and stability of the distal radio ulnar joint. *Scand J Plast Reconstr Surg* 19:17–25, 1985.
- Almquist EE: Evolution of the distal radioulnar joint. *Clin Orthop*, 5–13, 1992.
- Bachdahl M: The caput ulnae in rheumatoid arthritis: A study of the morphology, abnormal anatomy, and clinical picture. *Acta Rheum Scand* 5:1–75, 1963.
- Boler JM, Short WH, Werner FW, Yangida H: Biomechanical evaluation of three distal radioulnar joint reconstructions. SUNY Health Science Center, Syracuse, New York.
- Bowers WH: Instability of the distal radioulnar articulation. *Hand Clin* 7:311–327, 1991.
- Breen TF, Jupiter JB: Extensor carpi ulnaris and flexor carpi ulnaris tenodesis of the unstable distal ulna. *J Hand Surg [Am]*,14:612–617, 1989.
- Darrach W: Anterior dislocation of the head of the ulna. *Ann Surg* 56:802, 1912.
- Deitch MA, Stern PJ: Ulnocarpal abutment. Treatment options. *Hand Clin* 14:251–263, 1998.
- Dell PC: Distal radioulnar joint dysfunction. *Hand Clin* 3:563–583,1987.
- Drobner WS, Hausman MR: The distal radioulnar joint. *Hand Clin* 8:631–644, 1992.
- Ekenstam F: Osseous anatomy and articular relationships about the distal ulna. *Hand Clin* 14:161–164, 1998.
- Friedman SL, Palmer AK: The ulnar impaction syndrome. *Hand Clin* 7:295–310, 1991.
- Garcia-Elias M: Soft-tissue anatomy and relationships about the distal ulna. *Hand Clin* 14:165–176, 1998.
- Graham TJ, Fischer TJ, Hotchkiss RN, Kleinman WB: Disorders of the forearm axis. *Hand Clin* 14:305–316, 1998.
- Green DP, Hotchkiss RN, Pederson WC: Green's operative hand surgery. In: Book Green's operative hand surgery, Pages. New York, Churchill Livingstone, 1999.
- Hagert CG: The distal radioulnar joint. *Hand Clin* 3:41–50, 1987.
- Kihara H, Short WH, Werner FW, Fortino MD, Palmer AK: The stabilizing mechanism of the distal radioulnar joint during pronation and supination. *J Hand Surg [Am]* 20:930–936, 1995.
- Lichtman DM, Alexander AH: The wrist and its disorders. In: Book The wrist and its disorders, Pages. Philadelphia, Saunders, 1997.
- Lichtman DM, Ganocy TK, Kim DC: The indications for and techniques and outcomes of ablative procedures of the distal ulna. The Darrach resection, hemiresection, matched resection, and Sauve-Kapandji procedure. *Hand Clin* 14:265–277, 1998.
- Louis DS, Jebson PJ: The evolution of the distal radio-ulnar joint. *Hand Clin* 14:155–159, 1998.
- Melone CP, Jr, Nathan R: Traumatic disruption of the triangular fibrocartilage complex. Pathoanatomy. *Clin Orthop* 65–73, 1992.
- Mikic ZD: Age changes in the triangular fibrocartilage of the wrist joint. *J Anat* 126:367–384, 1978.
- Minami A, Suzuki K, Suenaga N, Ishikawa J: The Sauve-Kapandji procedure for osteoarthritis of the distal radioulnar joint. *J Hand Surg [Am]* 20:602–608, 1995.
- O'Donovan TM, Ruby LK: The distal radioulnar joint in rheumatoid arthritis. *Hand Clin* 5:249–256, 1989.
- Osterman AL: Arthroscopic debridement of triangular fibrocartilage complex tears. *Arthroscopy* 6:120–124, 1990.
- Osterman AL, Terrill RG: Arthroscopic treatment of TFCC lesions. *Hand Clin* 7:277–281, 1991.
- Palmer AK: The distal radioulnar joint. *Orthop Clin North Am* 15: 321–335, 1984.
- Palmer AK: Triangular fibrocartilage disorders: injury patterns and treatment. *Arthroscopy* 6:125–132, 1990.
- Palmer AK, Werner FW: The triangular fibrocartilage complex of the wrist—anatomy and function. *J Hand Surg [Am]* 6:153–162, 1981.
- Palmer AK, Werner FW: Biomechanics of the distal radioulnar joint. *Clin Orthop* 26–35, 1984.
- Petersen MS, Adams BD: Biomechanical evaluation of distal radioulnar reconstructions. *J Hand Surg [Am]* 18:328–334, 1993.
- Potter HG, Asnis-Ernberg L, Weiland AJ, Hotchkiss RN, Peterson MG, McCormack RR, Jr.: The utility of high-resolution magnetic resonance imaging in the evaluation of the triangular fibrocartilage complex of the wrist. *J Bone Joint Surg Am* 79:1675–1684, 1997.
- Raskin KB, Beldner S: Clinical examination of the distal ulna and surrounding structures. *Hand Clin* 14:177–90, 1998.
- Richmond BJ, Belhobek GH, Recht MP, Piraino DW, Schils J: Imaging modalities for study of the distal ulnar region. *Hand Clin* 14:191–212, 1998.
- Sagerman SD, Zogby RG, Palmer AK, Werner FW, Fortino MD: Relative articular inclination of the distal radioulnar joint: a radiographic study. *J Hand Surg [Am]* 20:597–601, 1995.
- Schuind F, An KN, Berglund L, Rey R, Cooney WP, Linscheid RL, Chao EY: The distal radioulnar ligaments: a biomechanical study. *J Hand Surg [Am]* 16:1106–1114, 1991.
- Shapiro JS: The wrist in rheumatoid arthritis. *Hand Clin* 12:477–498, 1996.
- Tolat AR, Stanley JK, Trail IA: A cadaveric study of the anatomy and stability of the distal radioulnar joint in the coronal and transverse planes. *J Hand Surg [Br]* 21:587–594, 1996.
- Weiler PJ, Bogoch ER: Kinematics of the distal radioulnar joint in rheumatoid arthritis: an in vivo study using centrode analysis. *J Hand Surg [Am]* 20:937–943, 1995.
- Werner FW, An KN: Biomechanics of the elbow and forearm. *Hand Clin* 10:357–373, 1994.
- Wiesner L, Rumelhart C, Pham E, Comtet JJ: Experimentally induced ulno-carpal instability. A study on 13 cadaver wrists. *J Hand Surg [Br]* 21:24–29, 1996.