



A Simple Technique for Suture Passage During Arthroscopic Repair of SLAP Lesions

Gregory F. Carolan, MD¹
Benjamin J. Widmer, MD¹
Brian J. Sennett, MD¹
G. Russell Huffman, MD¹

¹ Department of Orthopaedic Surgery,
University of Pennsylvania,
Philadelphia, PA

Safe, cost-effective and reliable suture passing is essential in the successful treatment of superior glenoid labrum tears. We present a simple means of achieving these goals utilizing Neviaser's portal, an 18-gauge spinal needle and prolene suture. Retrieval and shuttling of the suture is facilitated in the superior capsular recess without violation of the supraspinatus tendon.

Tears of the superior labrum of the glenoid from anterior to posterior (SLAP) have been identified as a common source of shoulder pain and disability. Treatment of these injuries is dictated by their morphologic pattern as originally described by Snyder⁸ and later by Maffet³. Type II SLAP tears are defined as tears of the superior labrum off the glenoid rim at the location of the biceps anchor and are considered the most common type of tear seen at arthroscopy⁷. Arthroscopic reinsertion of the injured labrum and biceps anchor into the glenoid with the use of suture anchors has become the standard treatment for these injuries. We present a modification of the technique described by Nord et al⁵ utilizing Neviaser's⁴ portal.

Surgical Technique

Patient Positioning

After the successful administration of anesthesia the patient is examined in the supine position. During the examination under anesthesia, one should document both evidence of glenohumeral instability and any lack of rotation with the shoulder abducted in the scapular plane. We prefer the lateral decubitus position, but alternatively the patient may be placed in the beach chair position at the surgeon's discretion. After prepping and draping of the operative extremity, the arm is positioned using a distraction tower (Arthrex, Naples, FL.) in approximately 40° of abduction and slight forward flexion using 10 to 15 pounds of traction. The anatomy of the acromion, clavicle, scapular spine and coracoid process is marked on the skin using a pen.

Arthroscopic Portal Placement

When SLAP tears and posterior glenoid labrum tears are treated, the posterior portal is moved slightly more laterally and two centimeters inferiorly to the posterolateral edge of the acromion. A diagnostic arthroscopy is performed including inspection of the rotator cuff interval, the long head of the biceps brachii, the rotator cuff insertion, and the glenoid labrum. An anterior portal is then created through the rotator interval just above the superior edge of

the subscapularis using the outside-in technique as described by Lo et al². This involves localization with an 18-gauge spinal needle and creation of the portal under direct visualization. A 5 to 7mm cannula is placed in this position. The long head of the biceps brachii tendon is pulled toward the subscapularis insertion and into the glenohumeral joint to inspect for tendinopathy within the bicipital groove as well as to detect biceps tendon instability. If significant pathology exists, consideration for biceps tenodesis with or without glenoid labral repair is considered depending on the patient's age and activity level.

After probing the labrum and confirming a Type II SLAP lesion, the superior glenoid articular margin is prepared with either an arthroscopic shaver, burr, or rasp via the anterior portal. This is most easily accomplished prior to placing a cannula through the anterior portal. We prefer preparing the glenoid articular margin with a bone-cutting shaver and subsequently placing a 5mm cannula through the anterior portal. Using the outside-in technique, an anterosuperolateral portal (ASL portal) is placed anterior to the leading edge of the supraspinatus and posterior to the long head of the biceps tendon². The superficial landmark for this portal is the anterolateral edge of the acromion. This portal is placed laterally in the rotator interval to allow an optimal angle for anchor placement both anterior and posterior to the biceps anchor. A 5mm cannula is of sufficient size for drilling and suture management. Except in the case of tear extension into a posterior Bankart lesion, we have not found it necessary or beneficial to use a larger cannula for this portal or to violate the supraspinatus myotendonous junction with a Portal of Wilmington.

For lesions that extend farther posteriorly, the posterolateral portal (Portal of Wilmington) may be used. However, we prefer to use the standard posterior viewing portal if it is initially placed more laterally in anticipation of such a lesion. This allows the surgeon to utilize this portal while viewing from the anterior interval

Corresponding Author:

G. Russell Huffman, MD
Department of Orthopaedic Surgery
Penn Sports Medicine Center
University of Pennsylvania
3400 Spruce Street, 2 Silverstein
Philadelphia, PA 19104
Russell.Huffman@uphs.upenn.edu

portal. In the latter scenario, the superior interval portal may be used for suture management. Even if placed medially and utilized without a cannula, the Portal of Wilmington may violate the rotator cuff tendon². For this reason, we prefer an interval portal, anterosuperolateral portal and a laterally-based posterior portal as previously described.

Repair of Lesion

With the arthroscope in the posterior portal, the location of the first suture anchor is determined. Using the “deadman’s angle” concept of Burkhart¹, a single armed suture anchor is placed at a 45° angle to the glenoid through the ASL portal. After the anchor is placed, both suture limbs are now coming out of the ASL cannula. With a crochet hook or suture retriever in the anterior portal, the suture limb closest to the labrum is retrieved for passage through the labrum.

Neviaser’s portal, as defined by the convergence of the scapular spine, the acromioclavicular joint and the clavicle, is identified. An 18-gauge spinal needle with its trochar in place is inserted and advanced laterally toward the superior glenoid. To prevent potential injury to the suprascapular nerve which is lying deep and medial to this area, it is important to make sure the spinal needle is placed at a shallow angle towards the glenoid. The spinal needle is visualized piercing the superior glenohumeral capsule (Figure 1). The position of the needle should be directly lateral to the suture anchor, as this location determines where the suture will be brought through the labrum. Once the position is confirmed, the needle is advanced through the superior labrum taking care to enter the labrum separately from the capsule.

In some instances, it is difficult to observe the recess between the medial capsule and the labrum due to extensive synovitis or loss of capsular integrity making later retrieval of the suture challenging. If this is encountered, a non-penetrating suture retriever is inserted through the ASL portal, and its jaws are placed around the shaft of the spinal needle in the recess between the capsule and labrum taking care to grab as little




Figure 1. An 18-gauge spinal needle with the trochar left in place is placed percutaneously through the Neviaser portal into the superior capsular recess. It is then positioned opposite the previously placed suture anchor and passed through the glenoid labrum. One limb of suture from the anchor is retrieved out of the anterior cannula.

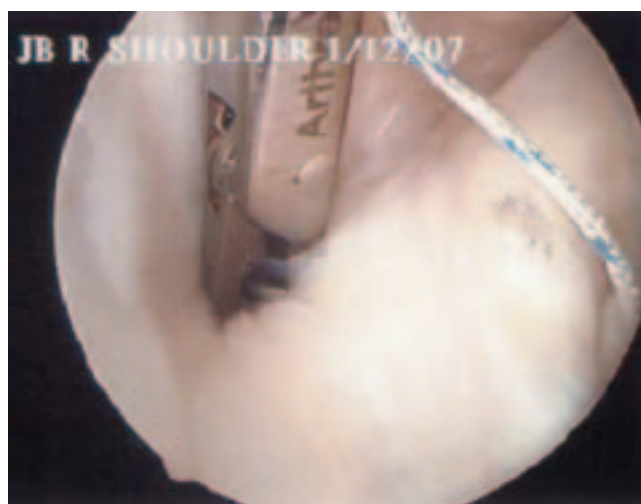


Figure 2. A suture retriever is introduced into the superior recess through the anterosuperolateral cannula and placed around the shaft of the spinal needle. The trochar of the spinal needle is withdrawn and a monofilament suture is placed through the needle and retrieved out of the anterior cannula.

soft tissue as possible (Figure 2). In cases with significant synovitis, this may be done by feel if direct visualization is not possible. An assistant maintains the grasper in this position during suture passage.

The trochar is withdrawn from the spinal needle and a free #1 or 0-monofilament suture is inserted into the spinal needle. Next the suture is grasped inside the joint with a suture grasper and retrieved through the anterior interval portal. The spinal needle is slowly withdrawn while maintaining the suture retriever in place. It is important to turn the bevel of the needle away from the suture while withdrawing so as not to cut the suture. After the needle has been withdrawn, the suture remains captured in the jaws of the suture retriever (Figure 3), and it is retrieved through the anterior cannula. A simple knot is tied in the monofilament around the suture limb from the anchor that is to be passed through the labrum. The end of the monofilament suture coming out of the Neviaser’s portal is then pulled, bringing the suture limb from the anchor through the labrum and out




Figure 3. The spinal needle is then withdrawn from the glenohumeral joint leaving the monofilament suture captured within the suture retriever’s jaws.



Figure 4. As the suture from the anchor is shuttled through the glenoid labrum, it is already captured within the suture retriever and ready to be retrieved through the ASL portal. Even in cases in which the spinal needle failed to enter the capsular recess or in which significant synovitis is present, capturing the needle and suture may be performed in the same fashion.

of the skin in Neviaser's area. During this process the suture retriever is held by the assistant in the ASL portal and retrieval of the suture limb is facilitated (Figure 4). Through the ASL portal, the suture that has been passed through the labrum is retrieved from the recess. If the earlier step of placing the suture retriever around the spinal needle was performed and the assistant has maintained closure of the retriever during these steps, the suture that has been shuttled through the labrum should be located in the jaws of the instrument. Even in instances when the suture is shuttled in an extra-articular fashion thru the superior labrum and outside of the superior glenohumeral capsule, the suture limb may be easily retrieved through the capsule by simply withdrawing the closed retriever out through the ASL portal. In this scenario, a small capsular rent is created as the suture is withdrawn. Both suture limbs are now coming out the ASL

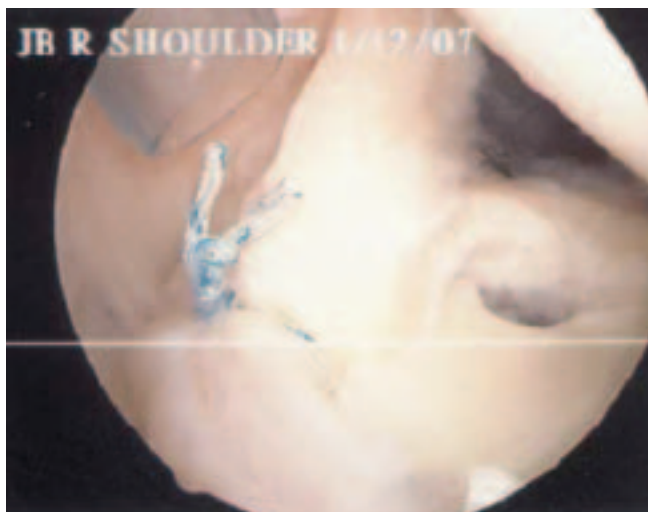

Figure 5. Arthroscopic knot tied superiorly on the labrum away from the articular surface.

portal. After identification of the suture limb traversing the labrum as the post, a standard arthroscopic knot is tied high and medial to the labrum to avoid the articular surface (Figure 5). These steps are repeated if additional anchors are needed.

Discussion

Nord et al⁵ described a simple and reproducible technique to repair SLAP lesions utilizing a tissue penetrator through Neviaser's portal. While they reported no complications regarding the suprascapular nerve, the use of such a large instrument in less skilled hands may place the nerve at risk more so than a spinal needle, although this is speculative. We have proposed a novel technique involving percutaneous placement of a spinal needle rather than a formal incision and tissue penetrator.

While different arthroscopic techniques to repair Type II SLAP lesions have been described^{5,6,9,10}, some techniques afford only a small purchase of the glenoid labrum. Utilization of Neviaser's portal allows suture placement medially enough to encircle the entirety of the detached or torn labrum. Regardless of the technique used in passing suture, a common step involves retrieval of the suture from an intra-articular position after it is passed thru the labrum from the superior capsular recess. In our experience, this recess and consequently the suture limb can be challenging to visualize especially in cases with excessive synovitis, capsular contraction, or in instances when intra-articular pressure is lost due to violation of the capsule. In order to find the suture the synovium or capsule may need to be debrided or ablated with a thermal device, potentially placing the suprascapular nerve at risk for injury. We have found the technique of localizing and grasping the spinal needle with a suture retriever through an anterosuperior lateral portal a safe, simple and cost-effective means of reliably shuttling suture through the superior glenoid labrum in the repair of SLAP lesions.

References

1. Burkhart SS. The deadman theory of suture anchors: observations along a South Texas fence line. *Arthroscopy* 11:119, 1995.
2. Lo IK, Lind CC, and Burkhart SS. Glenohumeral arthroscopy portals established using an outside-in technique: neurovascular anatomy at risk. *Arthroscopy* 20:596, 2004.
3. Maffet MW, Gartsman GM, and Moseley B. Superior labrum-biceps tendon complex lesions of the shoulder. *Am. J. Sports Med.* 23:93, 1995.
4. Neviaser TJ. Arthroscopy of the shoulder. *Orthop. Clin. North Am.* 18:361, 1987.
5. Nord KD, Masterson JP, and Mauck BM. Superior labrum anterior posterior (SLAP) repair using the Neviaser portal. *Arthroscopy* 20 Suppl 2:129, 2004.
6. O'Brien SJ, Allen AA, Coleman SH, and Drakos MC. The trans-rotator cuff approach to SLAP lesions: technical aspects for repair and a clinical follow-up of 31 patients at a minimum of 2 years. *Arthroscopy* 18:372, 2002.
7. Snyder SJ, Banas MP, and Karzel RP. An analysis of 140 injuries to the superior glenoid labrum. *J. Shoulder. Elbow. Surg.* 4:243, 1995.
8. Snyder SJ, Karzel RP, Del Pizzo W, Ferkel RD, and Friedman MJ. SLAP lesions of the shoulder. *Arthroscopy* 6:274, 1990.
9. Wolf BR, Selby RM, Dunn WR, and MacGillivray JD. Lasso repair of SLAP or Bankart lesions: a new arthroscopic technique. *Arthroscopy* 20 Suppl 2:125, 2004.
10. Yian E, Wang C, Millett PJ, and Warner JJ. Arthroscopic repair of SLAP lesions with a bioknotless suture anchor. *Arthroscopy* 20:547, 2004.