



# Anterior Hip Dislocation Five Months After Hip Arthroscopy: A Case Report and Review of the Literature

<sup>1</sup>Daniel C. Austin, BA

<sup>2</sup>John G. Horneff III, MD

<sup>3</sup>John D. Kelly IV, MD

<sup>1</sup>Perelman School of Medicine,  
University of Pennsylvania,  
Philadelphia, PA

<sup>2</sup>Department of Orthopaedic Surgery,  
University of Pennsylvania,  
Philadelphia, PA

## Introduction

Hip arthroscopy has increased in frequency over 300% between 2004 and 2009, as it has become an important technique used most often to treat diagnoses of labral tears or femoroacetabular impingement.<sup>1,2</sup> The procedure is most commonly performed in young adults aged 20-39 years and has been found to be an effective intervention for getting athletes back to their sport.<sup>1,3</sup> An important consideration in young active patients is the complication rate associated with a procedure. Notably, hip arthroscopy has been observed to be a low-risk intervention.<sup>4</sup> The hip arthroscopy complication rate has been reported to be 7.5% for minor complications, such as iatrogenic chondrolabral injury or transient neuropraxia, and 0.58% for major events, including post-operative dislocation, pulmonary embolus, and death.<sup>2</sup>

Dislocation has proven to be an exceedingly rare complication of hip arthroscopy with a systematic analysis documenting only four dislocation events out of 6,134 cases.<sup>2</sup> Although rare, these dislocation events, along with cadaveric studies, have highlighted the role of the iliofemoral ligament in anterior subluxation and overall hip stability.<sup>5-6</sup> On the whole, these observations have encouraged arthroscopists to minimize capsulotomies and repair the ligaments upon completion.<sup>5,7-9</sup> The previous reports of post-arthroscopy hip dislocation have occurred in the postoperative time period ranging from the recovery room to up to two months postoperatively after falling.<sup>10-11</sup> We report on a case of atraumatic dislocation that occurred in a high-level collegiate track and field athlete while jumping five months after hip arthroscopy. To our knowledge, this case represents the most remote dislocation event ever reported following arthroscopy and describes a novel mechanism of post-operative subluxation in athletes.

## Case Report

A 19-year-old collegiate high-jumper presented to our Sports Medicine Clinic with chronic right hip and groin pain along with a clicking

and catching sensation associated with hip movement. Her exam was notable for a positive impingement sign and decreased right hip internal rotation. An MRI of her right hip showed labral fraying, a Cam lesion, and a questionable Pincer anomaly. Given the patient's symptoms and findings on imaging, hip arthroscopy was recommended.

The patient was taken to the operating room, and the hip joint was first accessed through a standard anterolateral portal. A routine anterior portal was then created, and a modest "T" capsulotomy was performed along the femoral neck to gain access to the femoral head. A "wave sign" was visible within the acetabulum, confirming the diagnosis of Cam impingement. No other impingement lesions within the acetabulum or labrum were visualized except slight labral fraying, which was addressed with debridement before traction was released. Next, a conservative femoral neck resection was performed based upon the limited amount of impingement visualized. Finally, the psoas tendon was partially released because of the patient's history of anterior "snapping." The capsule was not closed. All instrumentation was then removed, and the portals were closed with sutures in standard fashion.

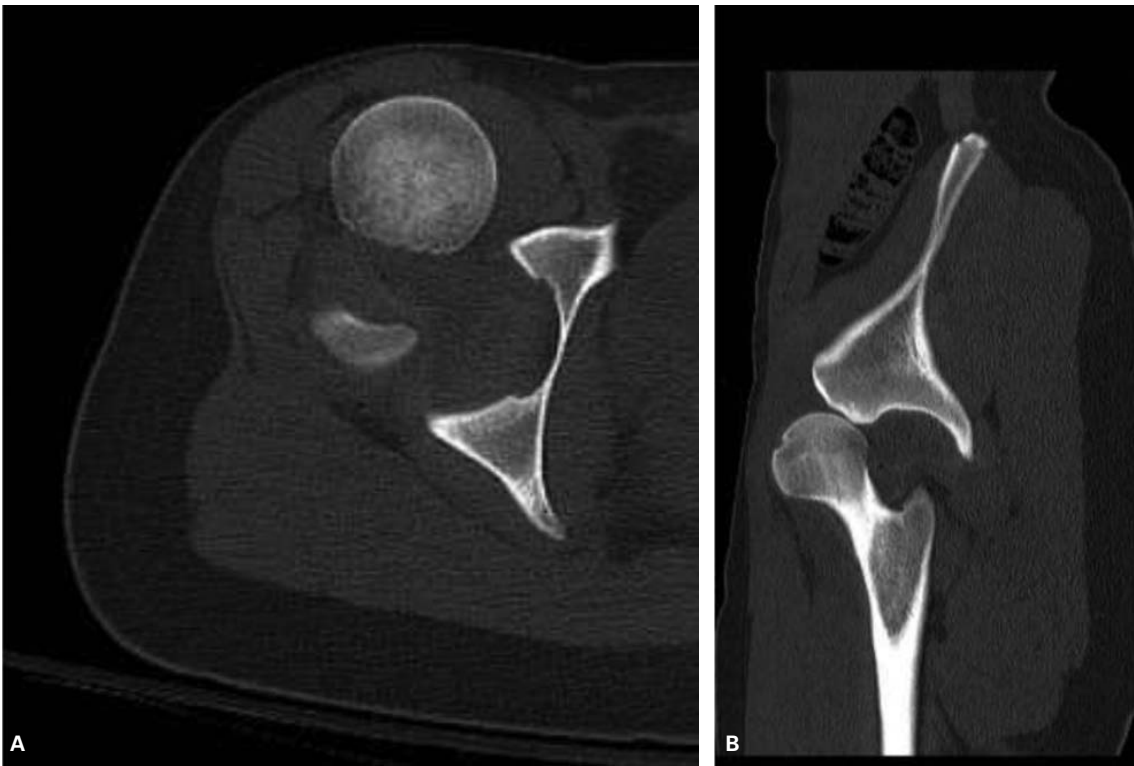
The patient recovered well in the immediate postoperative period and was cleared to return to full activity at the twelve week postoperative visit. She returned to competition as a high and long jumper without incident. At 21 weeks after surgery, the patient returned to the office with a complaint of sudden anterior groin pain when jumping. On exam she had full range of motion and no sign of impingement. She was diagnosed with a hip flexor strain and urged to warm up thoroughly before activities. The following week, 22 weeks post-operatively, the patient felt a sudden excruciating pain when jumping. She was taken to the emergency room where she was found to have an anterior hip dislocation (Figure 1), and the joint was successfully closed reduced.

After this incident, the patient underwent an MRI arthrogram of her right hip. No capsular tear was visible upon dye injection, and the

---

### Corresponding author:

John G. Horneff III, MD  
Department of Orthopaedic Surgery  
University of Pennsylvania  
3400 Spruce Street,  
2 Silverstein Pavilion  
Philadelphia, PA 19104  
John.Horneff@uphs.upenn.edu



**Figure 1.** Axial (A) and sagittal (B) CT cuts of anterior dislocation.

decision was made to treat the patient conservatively with no additional surgery at this time. She “red-shirted” her track and field season and focused on rehabilitating her hip. The patient was last seen approximately ten months post-operatively, four months after her dislocation, and was doing well without pain or activity limitations.

### Prior Reports and Relevant Literature

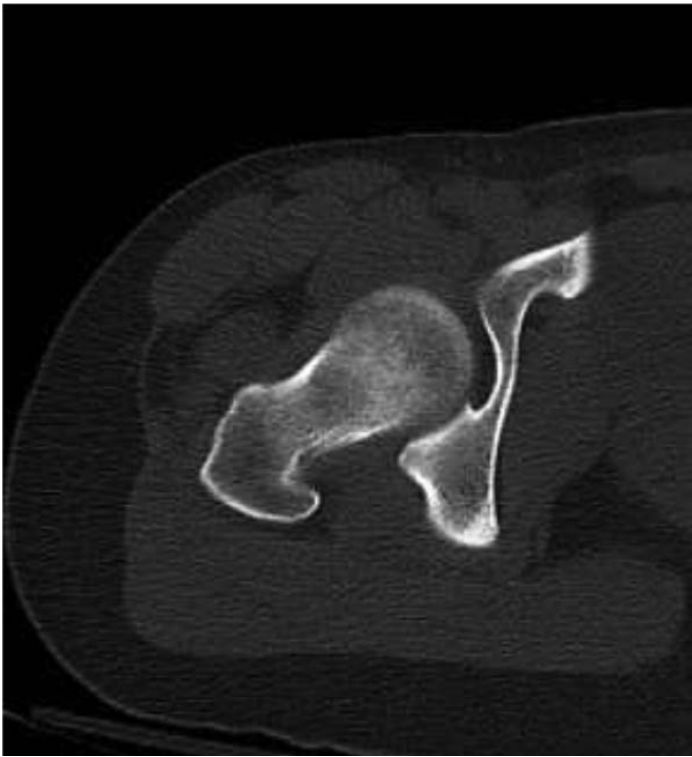
Though a rare complication of hip arthroscopy, postoperative dislocation is an important consideration for orthopaedic surgeons. Previous case reports regarding dislocation after arthroscopy highlighted dislocations that occurred earlier in the recovery period compared to our patient. Such reports have noted dislocations as soon as in the recovery room up to two months postoperatively after minor trauma.<sup>10-13</sup> Multiple causes of instability have been implicated, including excessive resection of the anterior acetabular rim, over-resection of the labrum in a patient with hip dysplasia, capsulotomy without repair in a ligamentously-lax patient, or a multifactorial etiology.<sup>10-13</sup> Ranawat *et al* reported a case most closely resembling our own as a woman who underwent hip arthroscopy for right hip pain and “popping.”<sup>11</sup> The patient was noted to have a labral tear with a Cam lesion and subsequently underwent labral repair, Cam lesion resection, and capsular plication that included the iliofemoral ligament. Two months after her operation, the patient sustained a fall down a short flight of stairs, resulting in an anterior hip dislocation that was closed reduced in the emergency room and treated with ten weeks of physical therapy and crutch use. She found no relief and eventually underwent a repeat arthroscopy, which noted a tear in the anterior capsule and iliofemoral ligament

that had previously been repaired. The authors discussed the importance of the iliofemoral ligament and how violation of the structure in anterior capsulectomy, although commonly performed by arthroscopists for exposure, is detrimental to hip stability and should be repaired and protected in the postoperative rehabilitation protocol.<sup>11</sup> The crucial role of the iliofemoral ligament in preventing anterior translation, and in hip stability overall, has been shown in anatomic cadaver studies.<sup>5,6</sup> Many other recent studies have highlighted the importance of capsular repair and urge all arthroscopists to consider a repair at the end of the case.<sup>5,7-9</sup>

### Discussion

The important role of both dynamic and static stabilizers of the hip in post-arthroscopy patients has been described thoroughly in the literature.<sup>10,13</sup> While the hip capsule of the patient in this case appears to have healed completely, as shown by the lack of dye extravasation in her MR arthrogram, a sutured closure of the capsule may have provided a more stable, less lax construct better able to prevent translation of the femoral head. Capsule management is a critical component in hip arthroscopy as the surgeon needs to provide adequate visualization to ensure an adequate resection while minimizing the capsulotomy to maintain stability.<sup>14</sup> This case strongly supports the recent trend in the literature to perform capsular repair, notably that of the iliofemoral ligament.

However, we believe the identification of a partial psoas tendon release as a cause of instability has not yet been investigated. The iliopsoas tendon is the common tendon connecting the psoas and iliacus muscles arising from their respective origins of the transverse processes of T12 to L5 and



**Figure 2.** Axial CT cut of reduced hip displaying anteversion.

iliac fossa to the lesser trochanter.<sup>9</sup> As the hip is extended, the iliopsoas tendon moves medially and lies in close proximity to the anterior joint capsule.<sup>14</sup> Although it is an active hip flexor, the iliopsoas tendon produces its greatest passive tension across the joint when the hip is in extension.<sup>15</sup> We believe that the partial psoas release in this case, in the setting of an anteverted acetabulum, could have been another cause of hip joint instability. As can be seen in the post-subluxation imaging (Figure 2), the patient has an anteverted femoral neck measuring approximately 30 degrees. We postulate that psoas release should be avoided in patients with significant anteversion, as it may be an under-appreciated dynamic stabilizer of the hip when this anatomy is present.

## Conclusion

The atraumatic dislocation experienced by our patient five months post-operatively, is over twice as long as any previously reported dislocation and raises awareness about the long-term effects that hip arthroscopy can have on hip joint stability. Furthermore, this case encourages surgeons to be particularly cautious with allowing jumping athletes to return to sport. The biomechanics of successful long jumpers, triple jumpers,

and high jumpers all require the athlete to plant their foot and extend their hip significantly at takeoff. This mechanism likely played a critical role in the anterior dislocation seen in our patient. The fact that the patient experienced pain with jumping in the week prior to the dislocation also makes the point that groin pain with jumping after hip arthroscopy could be indicative of capsular stretching or damage and should alert the patient and treating physician that healing has not fully occurred. We believe that the capsulotomy without repair, along with femoral anteversion and a partial psoas release, played a major role, creating enough hip instability that the patient was able to dislocate atraumatically while at track practice. The experience with this patient has encouraged us to agree with current literature guiding arthroscopists to minimize capsulotomies, repair the capsule before closure, and encourage a gradual rehabilitation protocol to full activity.

## References

1. Montgomery SR, Ngo SS, Hobson T, et al. Trends and demographics in hip arthroscopy in the United States. *Arthroscopy*. 2013; 29(4):661-665.
2. Harris JD, McCormick FM, Abrams GD, et al. Complications and Reoperations During and After Hip Arthroscopy: A Systematic Review of 92 Studies and More Than 6,000 Patients. *Arthroscopy*. 2013; 29(3):589-595.
3. Alradwan H, Philippon MJ, Farrokhyar F, et al. Return to Preinjury Activity Levels After Surgical Management of Femoroacetabular Impingement in Athletes. *Arthroscopy*. 2012; 28(10):1567-1576.
4. Clarke MT, Arora A, Villar RN. Hip Arthroscopy: Complications in 1054 Cases. *Clin Orthop Relat Res*. 2003; 406:84-88.
5. Myers CA, Register BC, Lertwanich P, et al. Role of the acetabular labrum and the iliofemoral ligament in hip stability: an in vitro biplane fluoroscopy study. *Am J Sports Med*. 2011;39(Suppl):85S-91S.
6. Martin HD, Savage A, Braly BA, et al. The function of the hip capsular ligaments: a quantitative report. *Arthroscopy*. 2008; 24(2):188-195.
7. Domb BG, Philippon MJ, Giordano BD. Arthroscopic capsulotomy, capsular repair, and capsular plication of the hip: relation to atraumatic instability. *Arthroscopy*. 2013; 29(1):162-173.
8. Harris JD, Slikker W III, Gupta AK, et al. Routine Complete Capsular Closure During Hip Arthroplasty. *Arthrosc Tech*. 2013; 2(2):e89-94.
9. Bedi A, Galano G, Walsh C, et al. Capsular Management During Hip Arthroscopy: From Femoroacetabular Impingement to Instability. *Arthroscopy*. 2011; 27(12):1720-1731.
10. Matsuda DK. Acute Iatrogenic Dislocation Following Hip Impingement Arthroscopic Surgery. *Arthroscopy*. 2009; 24(4):400-404.
11. Ranawat AS, McClincy M, Sekiya JK. Anterior dislocation of the hip after arthroscopy in a patient with capsular laxity of the hip. A case report. *J Bone Joint Surg Am*. 2009; 91(1):192-197.
12. Souza BG, Dani WS, Honda EK, et al. Do complications in hip arthroplasty change with experience? *Arthroscopy*. 2010; 26(8):1053-1057.
13. Benali Y, Katthagen, BD. Hip Subluxation as a Complication of Arthroscopic Debridement. *Arthroscopy*. 2009; 25(4):405-407.
14. Ilizaliturri VM Jr, Camacho-Galindo J. Endoscopic Treatment of Snapping Hips, Iliotibial Band, and Iliopsoas Tendon. *Sports Med Arthrosc Rev*. 2010; 18(2):120-127.
15. Neumann DA. Kinesiology of the hip: a focus on muscular actions. *J Orthop Sports Phys Ther*. 2010;40(2):82-94.