



# Diagnosing Infection in Patients Undergoing Conversion of Prior Internal Fixation to Total Hip Arthroplasty

Daniel Gittings, MD<sup>1</sup>  
P. Maxwell Courtney, MD<sup>1</sup>  
Blair Ashley, MD<sup>1</sup>  
Patrick Hesketh, MD<sup>1</sup>  
Derek Donegan, MD<sup>1</sup>  
Neil Sheth, MD<sup>1</sup>

<sup>1</sup>Department of Orthopaedic Surgery  
University of Pennsylvania  
Philadelphia, PA

## Introduction

Hip fractures accounted for over 340,000 hospital admissions in 2008 and are expected to rise to over 580,000 by 2040 due to an aging population in the United States.<sup>1,2</sup> Patients initially managed with open reduction and internal fixation that result in nonunion, early fixation failure, and post traumatic arthritis can be effectively treated with either revision internal fixation (with or without bone grafting) or conversion to total hip arthroplasty (THA).<sup>1-11</sup> Although conversion THA for failed hip internal fixation has good results, previous reports demonstrate that conversion THA has an increased incidence of superficial and deep infection compared to primary THA.<sup>19</sup> Periprosthetic joint infection is a devastating complication in THA, resulting in a substantial morbidity to the patient and cost burden to the health care system, and the diagnosis is often unclear.<sup>20</sup>

Currently, there are no recommendations for the diagnosis and management of infection prior to conversion of prior internal fixation to THA. The purpose of this study is to identify the incidence of infection in patients undergoing conversion of prior internal fixation to THA. We investigated several preoperative risk factors for infection and evaluated the utility of preoperative erythrocyte sedimentation rate (ESR) and C-reactive protein (CRP) as screening tools to identify patients with occult infection.

## Materials & Methods

This study is an Institutional Review Board approved retrospective review of patients at a single institution who underwent conversion of prior internal fixation to THA from 2009-2014. We searched the hospital's patient database and identified 33 patients that underwent conversion of prior internal fixation to THA, were greater than 18 years of age, and had laboratory data for ESR and CRP. The study's primary outcome variable was the presence of infection diagnosed by positive culture results at the time of conversion THA or at short-term follow up. Patients diagnosed with infections preoperatively underwent either removal of hardware with antibiotic cement spacer implantation, staged conversion THA, and 6 weeks of intravenous antibiotics, or

single-staged conversion THA with an antibiotic cement-impregnated implant and 6 weeks of intravenous antibiotics. Patients with positive intraoperative cultures that were diagnosed as infected postoperatively were treated with a debridement and/or 6-week course of intravenous antibiotics. After conversion THA or infection treatment, patients were followed for at least 60 days postoperatively (mean follow up of 1 year, range 2-30 months).

An a priori power analysis indicated the need to enroll a minimum of 31 patients to detect a standard large effect size  $w = 0.5$ , assuming a type-I error rate of 0.05 and a power of 0.80. Medical co-morbidities, smoking history, body mass index (BMI), prior hip surgery, and preoperative inflammatory markers (ESR and CRP) were documented and analyzed with univariate and multivariate logistic regression analysis (Table 2). Because we could not assume our small sample size was normally distributed, continuous variables were compared using the non-parametric Mann-Whitney U test. Categorical variables were compared using the Chi-square test; when the observed or expected values were less than 5, the Fisher Exact Test was used (Table 1). Receiver operating characteristic (ROC) curves were then generated to determine test performance of traditional inflammatory markers, ESR and CRP. Statistical significance was set at  $p = 0.05$ .

## Results

The 33 patients in this study included 9 (26%) with a previous intramedullary nail, 8 (23%) with acetabular internal fixation, 2 (6%) with slipped capital femoral epiphysis internal fixation, and 10 (28%) with femoral neck percutaneous screws. There were 16 males and 17 females included in the study with a mean age of 56 years (range 19-88 years). This study included 6 infected patients (18%) and 27 non-infected patients (82%). Logistic regression analysis showed no significant differences in age, BMI, and co-morbidities including diabetes mellitus, cardiac disease, smoking history, obesity, morbid obesity, and advanced age over 70 years between the two groups (Table 2).

Mean ESR and CRP were significantly higher ( $p < 0.05$ ) in the infected group (41.6 mm/hr and 2.02 mg/dL) compared to the non-

**Table 1. Comparison of risk factors of patients undergoing conversion total hip arthroplasty who were both infected and non-infected**

Risk Factor	Infected (n = 6)	Non-infected (n = 27)	P value
Mean Age (years)	66.2	52.5	0.191
Mean BMI (kg/m <sup>2</sup> )	29.2	27.3	0.562
Mean Preoperative ESR (mm/hr)	41.6	19.3	0.003
Mean Preoperative CRP (mg/dL)	2.02	1.27	0.003
Diabetes (%)	1 (16)	2 (7)	0.464
Cardiac disease (%)	1 (16)	5 (19)	1.000
Smoking history (%)	2 (33)	7 (26)	1.000
Obesity (%)	1 (16)	3 (11)	1.000
Morbid Obesity (%)	1 (16)	2 (7)	0.464
Age > 70 years	3 (50)	6 (22)	0.309
ESR > 30 (%)	5 (83)	4 (15)	0.007
CRP > 1 (%)	4 (67)	4 (15)	0.037

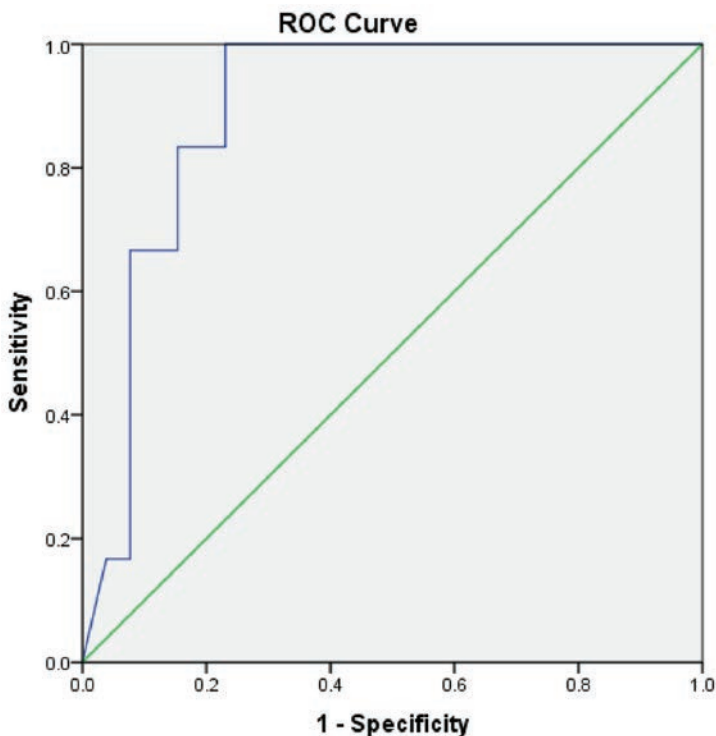
**Table 2. Univariate and multivariate logistic regression analysis on risk factors for infection at the time of conversion of prior hip surgery to THA**

Risk Factor	Univariate Analysis			Multivariate Analysis		
	Odds Ratio	95% Confidence Interval	p value	Odds Ratio	95% Confidence Interval	p value
Age > 70 years	3.50	0.55 – 22.20	0.186	7.77	0.24 – 425.61	0.315
Diabetes	2.50	0.18 – 33.17	0.507	4.60	0.01 – 2041.6	0.623
Cardiac disease	0.88	0.08 – 9.29	0.915	0.30	0.00 – 283.23	0.733
Smoking history	1.43	0.21 – 9.58	0.717	1.86	0.05 – 61.79	0.727
Obesity	1.60	0.14 – 18.72	0.716	1.68	0.02 – 132.73	0.816
Morbid Obesity	2.50	0.18 – 33.17	0.507	0.54	0.01 – 32.00	0.774
ESR > 30	28.75	2.62 – 315.42	0.001	27.66	1.08 – 705.88	0.044
CRP > 1	11.50	1.55 – 85.15	0.012	3.45	0.23 – 51.15	0.367

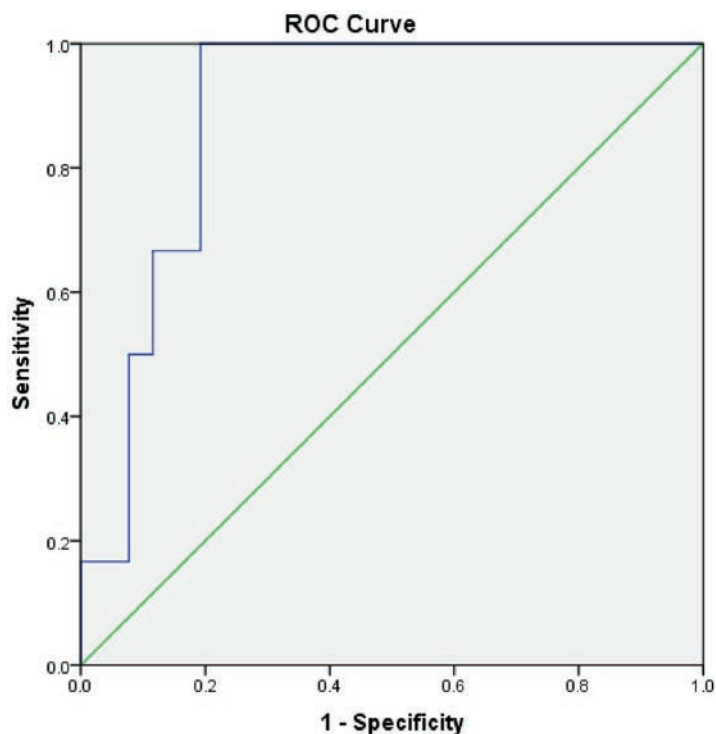
infected group (19.3 mm/hr and 1.27 mg/dL). There was a significant incidence ( $p < 0.05$ ) of elevated ESR > 30mm/hr and elevated CRP > 1mg/dL in the infected group (84% and 67% respectively) when compared with the non-infected group (15% and 15% respectively). Two (33%) of the infected patients had a CRP that was not elevated (CRP < 1mg/dL) but had an elevated ESR (ESR > 30mm/hr). Of the non-infected patients, 5 (18%) had either an elevated ESR or CRP, but these patients did not develop symptoms of prosthetic joint infection (PJI) during the follow-up period. Univariate analysis demonstrated that ESR > 30mm/hr (OR 28.75 (95% CI 2.62-315.42)) and CRP > 1mg/dL (OR 11.5 (95% CI 1.55-85.15)) were risk factors for the diagnosis of infection at the time of conversion THA. When controlling for confounding variables, multivariate analysis also showed that the odds ratio

for ESR > 30mm/hr was 27.66 (95% CI 1.08-705.88) and 3.45 (95% CI 0.23-51.15) for CRP > 1mg/dL.

ROC curves assessing the utility of inflammatory markers as a diagnostic tool for infection at the time of conversion THA showed a good fit for both ESR (AUC = 0.894) and CRP (AUC = 0.891) (Figure 1). Using a CRP > 0.7mg/dL had 100% sensitivity, 80.7% specificity, 100% negative predictive value, and 54.5% positive predictive value. Using an ESR > 30mm/hr had 83.3% sensitivity, 84.6% specificity, 95.6% negative predictive value, and 55.5% positive predictive value. Using a CRP > 0.7mg/dL or an ESR > 30mm/hr had 100% sensitivity, 76.9% specificity, 100% negative predictive value, and 50% positive predictive value. Using both CRP > 0.7mg/dL and ESR > 30mm/hr had 83.3% sensitivity, 88.4% specificity, 95.8% negative predictive value, and 62.5% positive predictive value.



**Figure 1a.** Receiver operating characteristic curve for preoperative ESR as predictor for infection at the time of conversion THA (AUC 0.894, 95% confidence interval 0.783 – 1.000).



**Figure 1b.** Receiver operating characteristic curve for preoperative CRP as predictor for infection at the time of conversion THA (AUC 0.891, 95% confidence interval 0.779 – 1.000).

## Discussion

This study has several limitations. First, we only included patients with inflammatory markers drawn prior to conversion THA. This results in a strong selection bias, as 97 patients who underwent conversion THA did not have an ESR or CRP.

We also recognize the limitations of our retrospective chart review with a relatively small sample size ( $n = 33$ ), which is only powered to detect large effect sizes. We risk committing type II error, particularly in the case of variables such as age and diabetes which were associated with increased risk of infection in our series, but not statistically significant. Finally, as a surgical procedure, conversion THA can be quite variable with patients having a variety of demographics, co-morbidities, and types of previous internal fixation procedures. These factors can limit our ability to make specific conclusions regarding the true impact of patient risk factors on infection prior to conversion THA. Nevertheless, given that the case mix of procedures in both groups was similar and comparable, certain generalizations about infection risks in patients undergoing conversion THA can be made.

## Conclusions

Given the complexity of conversion THA and morbidity of infection constant vigilance for occult infection must be maintained. The assessment for infection prior to conversion THA should begin with a detailed patient history. Symptoms such as a pain following a pain-free interval after ORIF, nighttime pain, or pain at rest should raise suspicion for infection. A physical examination should be performed and include an assessment of prior hip incisions. Following history and physical examination, routine laboratory studies should include CBC, ESR, and CRP. Elevated inflammatory markers should prompt a preoperative hip aspiration. Synovial fluid analysis including white blood cell count with differential as well as aerobic and anaerobic cultures should be performed<sup>24</sup>.

Elevated ESR and CRP are associated with infection prior to conversion THA. Although elevated ESR and CRP are useful tools to screen for occult infection prior to conversion THA, given the high incidence of discordance in inflammatory markers in this series, patients with both elevated and borderline inflammatory markers should prompt further evaluation with diagnostic hip aspiration including white blood cell count, differential, and culture prior to conversion THA surgery as the results may affect preoperative planning.

## References

1. Kyle RF, Cabanela ME, Russell TA, et al. Fractures of the proximal part of the femur. *Instr Course Lect* 44:227-253 (1995).
2. Kyle RF, Gustilo RB, Premer RF. Analysis of 622 intertrochanteric hip fractures. *J Bone Joint Surg Am* 61:216-221 (1979).
3. Baumgaertner MR, Solberg BD. Awareness of tip-apex distance reduces failure of fixation of trochanteric fractures of the hip. *J Bone Joint Surg Br* 79: 969-971 (1997).
4. Archibeck MJ, Carothers JT, Tripuraneni KR, et al. Total hip arthroplasty after failed internal fixation of proximal femoral fractures. *J Arthroplasty* 28:168 (2013).
5. D'Arrigo C, Perugia D, Carcangiu A, et al. Hip arthroplasty for failed treatment of proximal femoral fractures. *Int Orthop* 34:939 (2010).
6. Mohanty SS, Agashe MV, Sheth BA, et al. Outcome of total hip arthroplasty as a salvage procedure for failed infected internal fixation of hip fractures. *Indian J Orthop* 47:87 (2013).
7. Srivastav S, Mittal V, Agarwal S. Total hip arthroplasty following failed fixation of proximal hip fractures. *Indian J Orthop* 42(3):279 (2008).
8. Winemaker M, Gamble P, Petruccelli D, et al. Short-term outcomes of total hip arthroplasty after complications of open reduction internal fixation for hip fracture. *J Arthroplasty* 21:682 (2006).

9. Zhang B, Chiu KY, Wang M. Hip arthroplasty for failed internal fixation of intertrochanteric fractures. *J Arthroplasty* 19:329 (2004).
10. Min BW, Kim SJ. Avascular necrosis of the femoral head after osteosynthesis of femoral neck fracture. *Orthopedics* 34(5):349 (2011).
11. Mariani EM, Rand JA. Nonunion of intertrochanteric fractures of the femur following open reduction and internal fixation. Results of second attempts to gain union. *Clin Orthop Relat Res* 218:81 (1987).
12. Schnaser E, Scarcella NR, Vallier HA. Acetabular fractures converted to total hip arthroplasties in the elderly: how does function compare to primary total hip arthroplasty? *J Orthop Trauma* 28:694-699 (2013).
13. Franzen H, Nilsson LT, Stromqvist B, et al. Secondary total hip replacement after fractures of the femoral neck. *J Bone Joint Surg Br* 72:784-787 (1990).
14. Hagglund G, Nordstrom B, Lidgren L. Total hip replacement after nailing failure in femoral neck fractures. *Arch Orthop Trauma Surg* 103:125-127 (1984).
15. Nilsson LT, Jalovaara P, Franzen H, et al. Function after primary hemiarthroplasty and secondary total hip arthroplasty in femoral neck fracture. *J Arthroplasty* 9:369-373 (1994).
16. Tabshi, Waddell JP, Morton J. Total hip arthroplasty for complications of proximal femoral fractures. *J Orthop Trauma* 11:166-169 (1997).
17. Turner A, Wroblewski BM. Charnley low-friction arthroplasty for the treatment of hips with late complications of femoral neck fractures. *Clin Orthop* 185:126-130 (1984).
18. Khurana S, Nobel T, Merkow J, et al. Total hip arthroplasty for posttraumatic osteoarthritis of the hip fares worse than THA for primary osteoarthritis. *Am J Orthop* 44:321-325 (2015).
19. Baghoolizadeh M, Schwarzkopf R. Conversion total hip arthroplasty: Is it a primary or revision hip arthroplasty. *J Arthroplasty* S0883-5403 (15) 00536-7 (2015).
20. Kurtz S, Lau E, Watson H, et al. Economic burden of prosthetic joint infection in the United States. *J Arthroplasty* 27:61-65 (2012).
21. Milone M, Kamath A, Israelite C. Converting between high- and low-sensitivity C-reactive protein in the assessment of periprosthetic joint infection. *J Arthroplasty* 29:685-689 (2014).
22. McKinley JC, Robinson CM. Treatment of displaced intracapsular hip fractures with total hip arthroplasty: comparison of primary arthroplasty with early salvage arthroplasty after failed internal fixation. *J Bone Joint Surg Am* 84A:2010-2015 (2002).
23. Klingman M, Roffman M. Conversion Total hip replacement after failed internal fixation of intertrochanteric fracture. *Harefuah* 134:690-692 (1998).
24. Zhang B, Chiu K, Wang M. Hip arthroplasty for failed internal fixation of intertrochanteric fractures. *J Arthroplasty* 19:329-333 (2004).
25. Della Valle C, Parvizi J, Bauer TW, et al. American Academy of Orthopaedic Surgeons clinical practice guideline on: the diagnosis of periprosthetic joint infections of the hip and knee. *J Bone Joint Surg Am* 93:1355-1357 (2011).
26. Baek SH. Identification and preoperative optimization of risk factors to prevent periprosthetic joint infection. *World J Orthop* 5:362-367 (2014).
27. Phillips JE, Crane TP, Noy M, et al. The incidence of deep prosthetic infections in a specialist orthopaedic hospital: a 15-year prospective survey. *J Bone Joint Surg Br* 88:943-8 (2006).
28. Bozic KJ, Lau E, Kurtz S, et al. Patient-related risk factors for periprosthetic joint infection and postoperative mortality following total hip arthroplasty in Medicare patients. *J Bone Joint Surg Am* 94:794-800 (2012).
29. Berbari E, Mabry T, Tsaras G, et al. Inflammatory blood laboratory levels as markers of prosthetic joint infection: a systematic review and meta-analysis. *J Bone Joint Surg Am* 92:2102-2109 (2010).