



Immunohistochemical Analysis of Muscle Tissue Following Blunt Achilles Tendon Transection in a Rat Model

Tyler R. Morris¹
Benjamin R. Freedman¹
Pankti R. Bhatt¹
Joshua A. Gordon¹
Alexis A. Williams¹
Louis J. Soslowsky¹

¹McKay Orthopaedic Research Laboratory
Philadelphia, PA

Introduction

Achilles tendon tears are common musculoskeletal injuries that often require surgical repair.¹ An abundance of evidence exists that suggests tendon loading, to a certain limit, is beneficial to healing and may promote more mature and robust cellular architecture.² However, there is debate regarding whether surgical or non-surgical intervention is the optimum treatment strategy.³ There is a paucity of evidence regarding the effect of surgical treatment, the length of immobilization, and rehabilitation protocols on muscle tissue of the Achilles musculotendinous unit.^{4,5} A better understanding of how treatment of Achilles tendon tears affect the muscle tissue may result in improvements in immobilization protocols, rehabilitation and injury prevention.⁶ Therefore, the objective of this study was to elucidate the biological and structural effects of surgical and immobilization protocols on muscle tissue during early healing using immunohistochemistry. We hypothesized that prolonged immobilization, as well as non-repair, would result in immunohistochemical evidence of muscle remodeling compared to shorter immobilization lengths and repaired groups.

Methods

30 adult male Sprague-Dawley rats (400-450g) were used in this IACUC approved study. Animals received 2-weeks of treadmill training (up to 60 minutes at 10m/min) prior to surgical removal of the right central plantaris longus tendon and blunt transection of their right Achilles tendon. Animals were then divided into 4 groups: 1) surgical repair, using a modified Kessler technique, followed by 1 week of cast immobilization, 1 week of cage activity, and 1 week of treadmill exercise 2) surgical repair followed by 3 weeks of immobilization; 3) no surgical repair followed by 1 week of cast immobilization, 1 week of cage activity, and 1 week of treadmill exercise; and 4) no surgical repair followed by 3 weeks of cast immobilization. All animals were sacrificed at 3 weeks post-injury. Animals undergoing only 1 week of cast immobilization were considered “aggressive” rehabilitation (Agg), while those that underwent 3 weeks of immobilization were termed “conservative” rehabilitation (Cons). At sacrifice, the right Achilles musculotendinous units were dissected and processed for histological

analysis. Transverse muscle tissue samples were then harvested, embedded in optimal cutting temperature (OCT) compound, frozen in N-methyl butane, and sectioned at 20mm on a cryotome. Samples were stained with Laminin-DAPI for immunofluorescence and analyzed using a custom computer program to quantitatively elucidate cellularity, fiber size and shape, and nuclear centrality.⁷ Immunohistochemical protocols were developed to test for Collagens 1 & 3 (denoting structural properties of muscle tissue), IL-1 α & b, IL-6, and TNF- α (corresponding to remodeling and inflammatory pathways seen in muscle repair models).⁸ Samples were incubated with primary and secondary antibodies and incubated according to manufacturer specifications. DAB was used to label activity and analyzed using a quantitative software program denoting activity by percent area stained (imageJ, NIH). MMP activity (a marker of muscle fiber remodeling) was quantitatively measured using the Sensolyte 520 Generic MMP assay kit. All parameters assessed were compared between groups using one-tailed Student's t-tests, with significance set at $p \leq 0.05$.

Results

Results show that the rats in the non-surgical cohort treated with conservative rehabilitation had increased MMP activity compared to repair. Conversely, rats in the surgical cohort with conservative rehabilitation showed decreased Collagen 3, increased Collagen 1:3 ratio, and decreased MMP activity (Figure 1). No difference was seen between groups with regard to physical fiber properties, including fiber size, shape, and nuclear number or percent centrality (Figure 2). Immunohistochemical analysis showed conservatively treated animals had greater amounts of IL-1 α and IL-6 in non-repair groups, while TNF- α was decreased in repair rats treated conservatively compared to repair treated aggressively (Figure 3).

Discussion

Results suggest that non-repair of Achilles tendon transection results in higher levels of IL-1 α and IL-6, markers of muscle remodeling. These findings are consistent with previous data showing that non-repair results in significantly longer tendons, likely causing a decreased muscle tension and force output.⁴ Additionally, longer

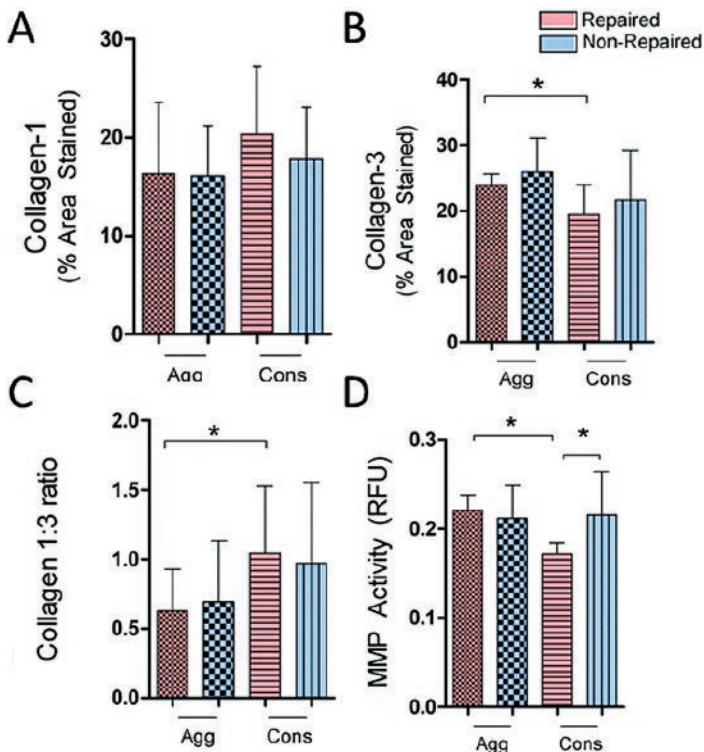


Figure 1. Muscle Structural Properties During Healing A) Collagen I B) Collagen III C) Collagen I:III ratio D) MMP Activity. Error bars: standard deviation, *: $p < 0.05$.

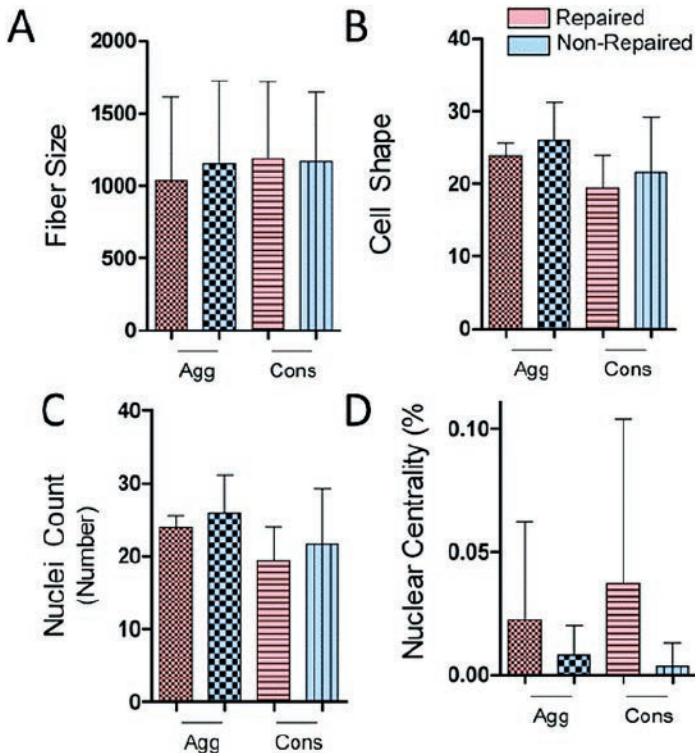


Figure 2. Muscle Physical Properties during Healing A) Fiber size B) Cell shape C) Nuclear count D) Nuclear Centrality. Error bars: standard deviation, *: $p < 0.05$.

periods of immobilization showed decreased TNF- α and a greater proportion of collagen 1, rejecting our hypothesis that increased immobilization would correspond to increasing muscle damage. This is in opposition to tendon findings, which

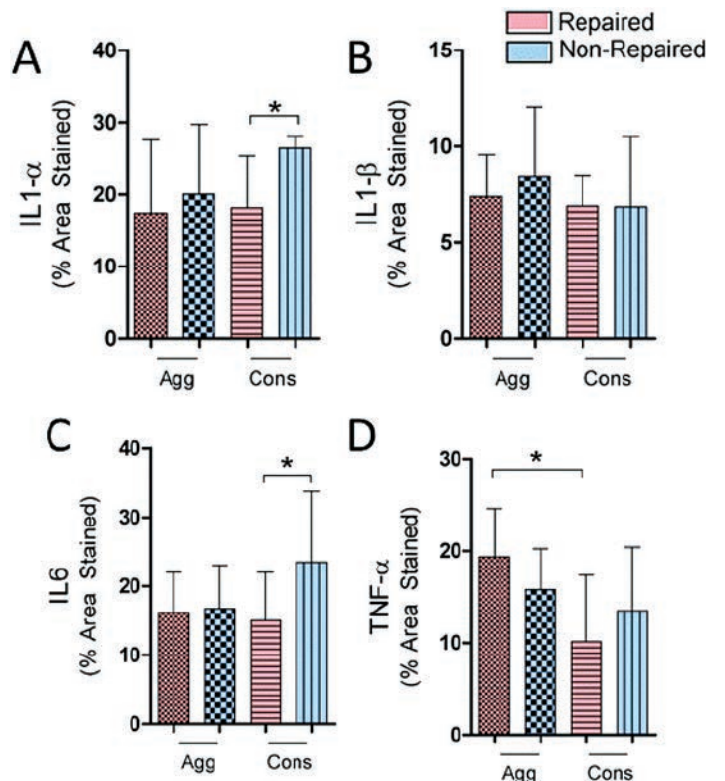


Figure 3. Muscle Remodeling and Repair during Healing A) IL 1-alpha B) IL 1-beta C) IL-6 D) TNF-alpha. Error bars: standard deviation, *: $p < 0.05$.

show increasing time of immobilization resulting in decreased range of motion at the ankle and worse functional properties.⁹ Taken together, this suggests that muscle and tendon tissue may have antagonistic responses to treatment modalities. Overall, findings show that surgical repair improves outcomes in muscle tissue, while increasing immobilization is beneficial to muscle tissue and may be detrimental to tendon.

Significance

Surgical repair and conservative rehabilitation, corresponding to increasing immobilization times, is beneficial to muscle tissue following Achilles tendon injuries in an animal model.

Acknowledgments

We acknowledge financial support from NIH/NIAMS R01AR064216, NIH/NIAMS P30AR050950, and the NSF GRFP. We thank Robert Zanes, Jennica Tucker, and Sarah Rooney for assistance.

References

- Suchak AA *et al.*, *FAI*, 26(11) 932-6, (2005).
- Wang J *et al.*, *Int J Clin Exp Med*, 15;8(1): 1144-9, (2015).
- AAOS *Guidelines for Achilles Tendon Repair*, (2009).
- Krochmal DJ *et al.*, *JSR*, 146(1):81-9, (2008).
- Freedman BR *et al.*, *MLTJ*, 4(2) 245-255, (2014).
- Peltz CD *et al.*, *JOR* 28(7): 841-5, (2010).
- Smith LR *et al.*, *Skeletal Muscle* 2044-5040-4-21, (2014).
- Bente KP *et al.*, *Phys Rev*, 88(4) 1379-1406, (2008).
- Kangas J *et al.*, *JOT* 54(6):1171-80, (2003).