



U·P·O·J

Aging Decreases Rat Achilles Tendon Vessel Density and Blood Flow after Injury

Corinne Riggan, BS¹
Susan Schultz, RDMS²
Chandra Sehgal, PhD²
Louis Soslowky, PhD¹

¹McKay Orthopaedic Research Laboratory,
University of Pennsylvania, PA

²Department of Radiology
University of Pennsylvania, PA

Introduction

Aging has significant effects on both maintenance of tendon health and tendon healing potential after injury^{1,2}. Clinical ultrasound studies have demonstrated reduced blood flow in uninjured tendons due to aging^{3,4} and cellular studies have demonstrated reduced vascular endothelial cell expansion and differentiation potential in tendon cell populations harvested from older age groups⁵. This suggests that tendons are subject to changes in vasculature that could alter their cellular responses, contributing to reduced healing capacity in the aged population. However, how aging affects the vascular response to injury in tendon is unknown. Therefore, the objective of this study is to evaluate the vascular response following Achilles tendon injury in adult and aged rats using both in vivo ultrasound measures of blood flow and ex vivo histological measures of vascular structure. We hypothesize that when compared to adult rats, aged rats will demonstrate a decrease in blood flow parameters, as well as a decrease in vascular density following injury.

Methods

Study Design

Under IACUC approval, 4 adult rats (4-5 months) and 5 aged rats (14-16 months) were used for this study. All animals underwent a bilateral Achilles incisional injury, followed by ultrasound imaging (n = 8-9 tendons/group) on day 7 post-injury, and sacrifice on the same day for histological evaluation (n = 8-9 tendons/group).

Surgical Protocol

Using aseptic technique, a skin incision was made on the medial side of the ankle, and the Achilles tendon was isolated. Using a 1.5mm flat scalpel blade, an incisional injury was made in the center of the tendon width in the mid-substance region. The tendon was left unrepaired and the skin was sutured closed.

Color Doppler Imaging

All animals underwent color Doppler imaging (Fig1A,B) on day 7 post-injury using the Vevo 2100 ultrasound system (VisualSonics Inc, Toronto) with a 40 MHz linear array transducer

(MS550). Briefly, animals were anesthetized and positioned with the ultrasound probe parallel to the long axis of the tendon, imaging the sagittal plane. The mean color level (average blood flow velocity), the fractional area (% area of Doppler signal), and the color weighted fractional area (weighted average of blood flow velocity/unit area) were quantified over the entire tendon area. Results were compared using Student's t-tests with significance set at $p < 0.05$.

Histological Analysis

After sacrifice, the Achilles tendons were dissected and processed using standard techniques. Sections were stained with hematoxylin-eosin (H&E) and graded by 3 blinded, independent graders for cell shape (1 = spindle to 3 = round) and cellularity (1 = less cells to 3 = more cells). Additionally, sections underwent immunohistological staining for CD34, a vascular endothelial cell marker, and graded by 3 blinded, independent graders for vessel density (1 = less dense to 4 = more dense) and vessel size (1 = small lumen diameter to 4 = large lumen diameter). Results were compared using Mann-Whitney t-tests with significance set at $p < 0.05$.

Results

Ultrasound analysis demonstrated a significant decrease in fractional area (Fig1C), mean color level (Fig1D), and color weighted fractional area (Fig1E) following injury in the aged group. Additionally, immunohistochemical evaluation (Fig2A,B) demonstrated a significant decrease in vessel density (Fig2C), but no change in vessel size (Fig2D) following injury in the aged group. H&E analysis of cell number and cell shape did not demonstrate differences between groups (data not shown).

Discussion

Results demonstrate significant changes in both blood flow, as shown by the decreased mean color level and color weighted fractional area measures, as well as vascular structure, as shown by the ultrasound fractional area and histological vessel density measures. Interestingly, the vessel size did not change, suggesting that the maturation of vessels that form is similar between groups. This data supports previous human

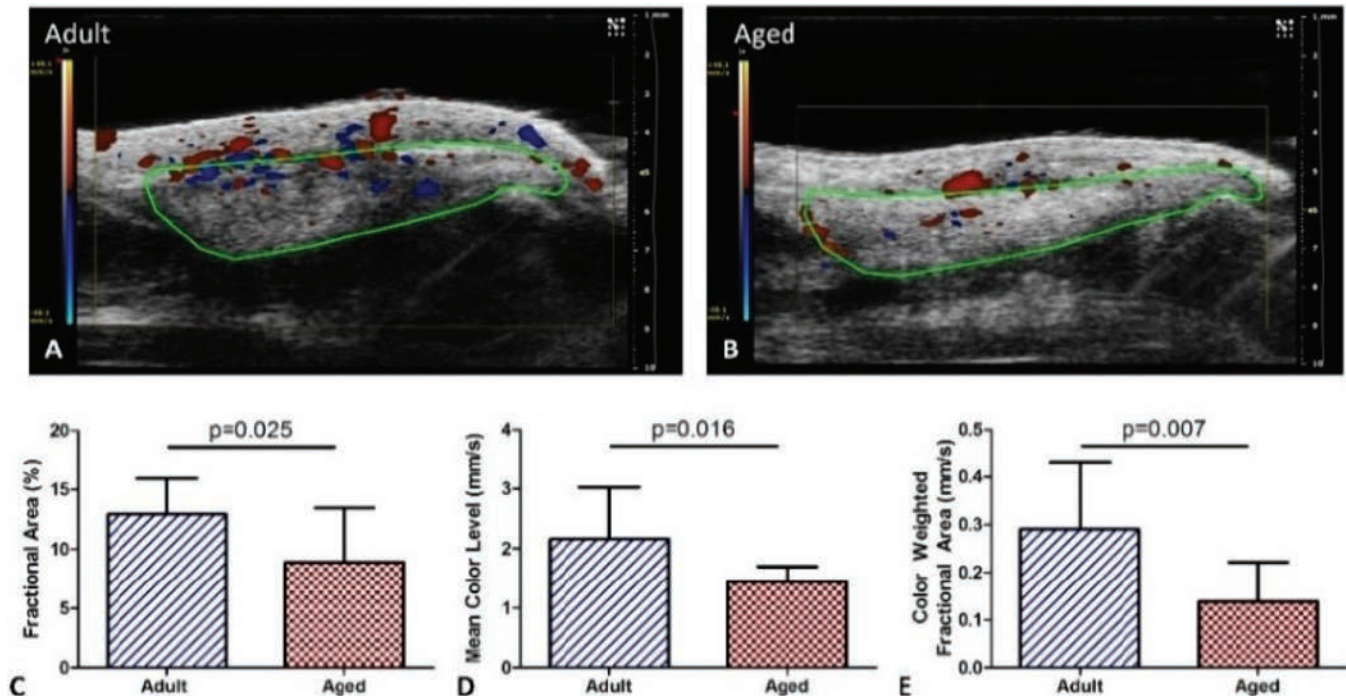


Figure 1. Representative color Doppler ultrasound images of (A) adult and (B) aged animals 1 week after injury (tendon ROI outlined in green). Ultrasound analysis of (C) fractional area, (D) mean color level, (E) color weighted fractional area demonstrating decreases in the aged group.

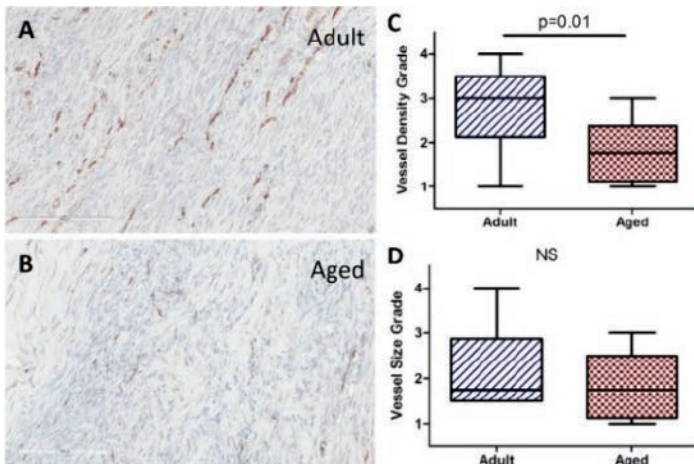


Figure 2. Representative images of (A) adult and (B) aged CD34 immunohistochemical staining (brown indicates presence of vascular endothelial cells). (A) Vessel density and (B) vessel size of adult and aged animals 1 week after injury.

ultrasound studies^{3,4}, showing decreased blood flow in elderly patients in both the uninjured Achilles and supraspinatus tendons. Additionally, the reduced vessel density could be explained by the decreased cell expansion or differentiation potential for vascular endothelial cells previously reported⁵. Future studies will evaluate the effect of vascular modulation on healing potential in both aged and adult animals using the delivery of pro- and anti-angiogenic factors after injury.

Significance

This study is the first to evaluate changes in vascular response due to aging after tendon injury in an animal model

using both in vivo measures of blood flow as well as ex vivo structural measures of vascularity. Data suggests that aging tendons undergo changes in both vasculature structure and function, which can alter cellular responses and healing capacity after injury, and could help explain the reduced healing potential of the aged population.

Acknowledgements

The authors thank Cody Hillin, Molly Minnig, Julianne Huegel, Kerrie Tiedemann, and the University of Pennsylvania Small Animal Imaging Facility. This study was funded by a NIH/NIAMS (P30AR050950) supported Penn Center for Musculoskeletal Disorders Imaging Core Seed Grant and a NSF Graduate Research Fellowship.

References

1. Yu TY, Pang JH, Wu KP, Chen MJ, Chen CH, Tsai WC. Aging is associated with increased activities of matrix metalloproteinase-2 and -9 in tenocytes. *BMC Musculoskelet Disord.* 2013 Jan 2;14:2. doi: 10.1186/1471-2474-14-2.
2. Kostrominova TY and Brooks SV. Age-related changes in structure and extracellular matrix protein expression levels in rat tendons. *Age (Dordr).* 2013 Dec;35(6):2203-14. doi: 10.1007/s11357-013-9514-2. Epub 2013 Jan 27.
3. Rudzki JR, Adler RS, Warren RF, Kadmas WR, Verma N, Pearle AD, Lyman S, Fealy S. Contrast-enhanced ultrasound characterization of the vascularity of the rotator cuff tendon: age- and activity-related changes in the intact asymptomatic rotator cuff. *J Shoulder Elbow Surg.* 2008 Jan-Feb;17(1 Suppl):96S-100S.
4. Langberg H, Olesen J, Skovgaard D, Kjaer M. Age related blood flow around the Achilles tendon during exercise in humans. *Eur J Appl Physiol.* 2001 Mar;84(3):246-8.
5. Uefuji A, Matsumoto T, Matsushita T, Ueha T, Zhang S, Kurosaka M, Kuroda R. Age-Related Differences in Anterior Cruciate Ligament Remnant Vascular-Derived Cells. *Am J Sports Med.* 2014 Jun;42(6):1478-86. doi: 10.1177/0363546514529092. Epub 2014 Apr 11.