



Hand Tips & Tricks: Wrist and Hand Radiography

Kristin Buterbaugh MD
Glenn Buterbaugh MD

Radiographs of the hand and wrist are frequently first line assessments in the work up of both acute and chronic hand and wrist complaints. However, there are a multitude of views, measurements, and variations in anatomy that can make evaluation of hand and wrist radiography daunting. When approaching radiography of the hand and wrist, it is best to have a systematic way to evaluate imaging. This article provides a framework for systematic review of radiographs of the wrist and hand.

Evaluation of the Hand

Standard hand radiographic projections include the posterior-anterior (PA) view, lateral view, and oblique view. In the PA view, the hand is placed palm down on the cassette with the X-ray beam angled at 90 degrees. The articular surface of distal radius makes smooth concentric arc with proximal carpal row, and the arcs of the articular surfaces of midcarpal joint are congruent and concentric. These arcs are frequently referred to as Gilula's Lines. Metacarpal-phalangeal (MCP) and interphalangeal (IP) joints should appear open in digits two through five. The soft tissues of the phalanges should be symmetric. In the lateral view, the radius and ulna should be superimposed along with the metacarpals. Fanning the fingers and abducting the thumb allow for visualization of all digits with open joint spaces. In the oblique view the hand is externally rotated 45 degrees from the PA position. In an appropriately positioned oblique view, the midshafts of the third through fifth metacarpals will not overlap, though the distal heads will. There should be no overlap of the second and third metacarpals.

When assessing these standard radiographs, common variations in anatomy include the presence of sesamoids. Sesamoids are rounded well corticated ossicles at palmar aspect of the metacarpal heads. These can be confused for fracture, so it is important to remember locations where they are typically noted. There are two sesamoids at the MCP joint of thumb and occasionally one at the IP joint. There is frequently a sesamoid present in the MCP joint of small finger and one or two in MCP joint of index finger⁵. An accessory ulnar styloid ossicle may also be noted on radiographs, a less common

anatomical variant which can be confused for fracture.

Since there is significant overlap between the carpal bones on standard views, many specific views have been developed to better visualize the carpus. We will focus on several of the carpal bone specific views including the scaphoid view, the carpal tunnel view, the semisupinated oblique view, the pisotriquetral view, and the Robert's view.

The scaphoid is best evaluated by an elongated PA view where the beam is angled 30 degrees cephalad with the wrist positioned in 10-15 degrees of ulnar deviation (Figure 1²). Ulnar deviation moves the scaphoid from the radius and presents its axis longitudinally. Angling the beam 30 degrees accounts for the volar tilt of the scaphoid allowing it to be evaluated en face with minimal superimposition.

The pisiform and the hook of hamate can be examined using the carpal tunnel view and the semisupinated oblique view. These views project the pisiform and the hook of the hamate volar to rest of carpus. The carpal tunnel view is an axial projection of the carpal tunnel. The hand placed in a hyperdorsiflexed position and

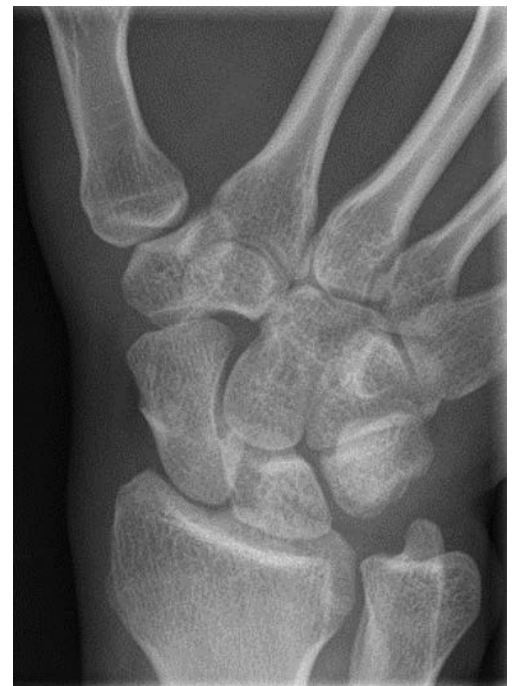

Figure 1. Photo credit: Daffner

the beam is aimed through the carpal tunnel. The view can be used to visualize hook of hamate, trapezium, and pisiform fractures (Hart Gaynor JBJS 1941). An alternative view for evaluating the hook of the hamate when concerned for fracture is the semi supine oblique radiograph. Positioning for a carpal tunnel view can be too painful in the setting of fracture. The semi supine oblique view positions the forearm in a neutral position with the beam centered on the thumb webspace. The thumb is maximally opposed and hand radially deviated. This brings the hook of the hamate into the thumb webspace (Figure 2⁸). Even with these specialized views, hook of the hamate fracture can be difficult to diagnose. If X-rays are negative but there remains clinical concern for fracture, a CT scan should be obtained.

The pisotriquetral view—also known as the All State View—is useful for the diagnosis or exclusion of pisotriquetral osteoarthritis. For this image, the hand is placed in a 30 degree supinated from neutral so that Lister's tubercle is most dorsal structure (Figure 3⁴). Although pisotriquetral osteoarthritis is uncommon, it is a well-described cause of pain over the ulnar aspect of the wrist.

The Roberts view evaluates the first trapezometacarpal and the scaphotrapezial joints the diagnosis of osteoarthritis. The trapezium is oblique to the remainder of the palm. Thus, in the Roberts view, the dorsum of thumb is placed on the plate in forced pronation as bulk of palm precludes joint from lying flat (Roberts 1936). We advocate the utilization of the Lewis modification which angles the beam 15 degrees proximally

to correct the offset of the trapezometacarpal joint from the horizontal (Figure 4⁶).

Evaluation of the Wrist

Standard wrist radiographs include the PA, lateral, and 45-degree semi-pronated oblique. These allow for improved evaluation of the distal radioulnar joint (DRUJ) and the distal radius.

In all views, it is important to note the position of wrist in space. Forearm orientation of wrist is based on the location of ulnar styloid, which always follows the olecranon. In neutral, the ulnar styloid is at the ulnar most aspect of the ulnar head on the PA view. However, in supination and pronation, the ulnar styloid will be in the center of the ulnar head. On the lateral view, the ulnar styloid will be dorsal in relation to the radius in supination and volar in pronation. Proximal convergence of the radial and ulnar shafts suggests pronation on the PA view. In contrast, parallel or proximally diverging shafts suggests supination. Additionally, the position of the wrist dynamically affects the measurement of ulnar variance. In supination and in radial deviation, the ulna appears relatively shorter. Negative ulnar variance also increases as the X-ray beam moves proximally³. Finally, wrist deviation should be noted in the assessment of the PA view. In radial deviation, lunate is half on and half off the ulnar border of the radius, whereas in ulnar deviation, the lunate is completely congruent with the radius.

When evaluating the DRUJ, the PA view assesses of degeneration and ulnar variance at the DRUJ, whereas the lateral view assesses alignment. Normal alignment should illustrate overlap of the radius and ulna on the lateral view with no dorsal or volar displacement. To ensure a good lateral in the unstable DRUJ, compare the relative positions of the distal pole of scaphoid and the pisiform (the most volar portions of the carpus) with the volar cortex of the capitate, which represents a relative midpoint. The pisiform should be transected in half by the volar cortex of the capitate, and pisiform should overlie the distal pole of the scaphoid. If the pisiform is volar to capitate anterior cortex, the image is supinated. If more dorsal, image is pronated (Figure 5¹).

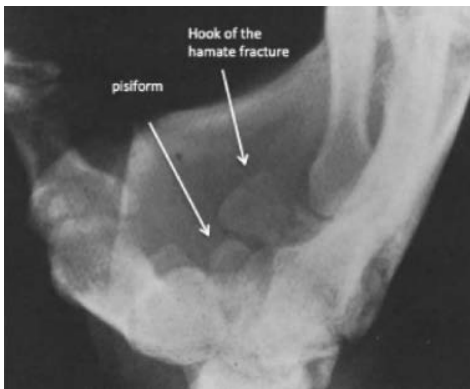


Figure 2. Photo credit: Papilion 1988

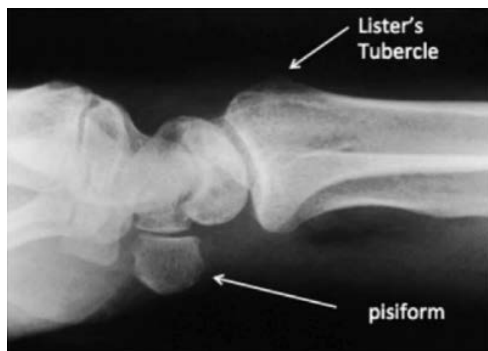


Figure 3. Photo credit: Gardner-Thorpe 1999

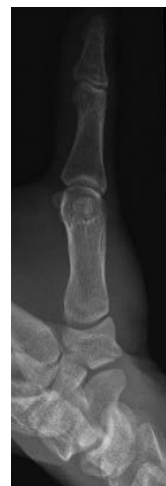

Figure 4. Photo credit: Ladd 2013

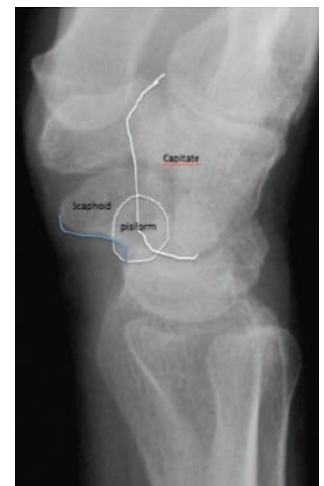

Figure 5. Photo credit: Amrami 2010

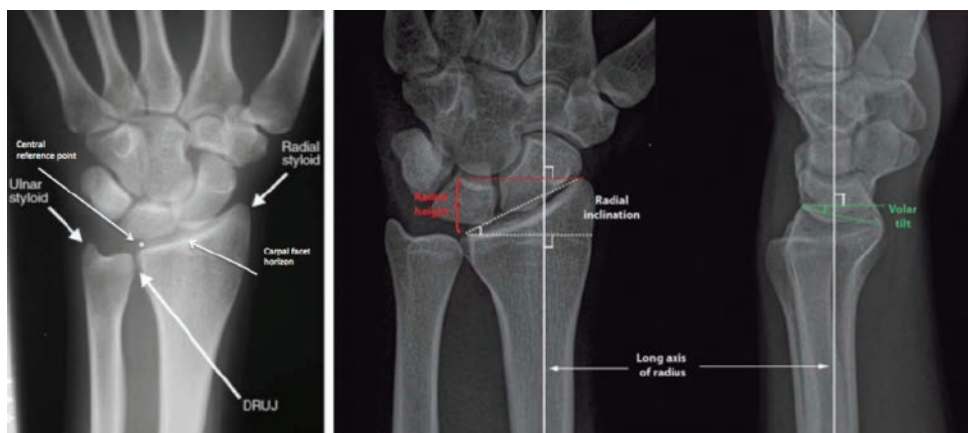


Figure 6. Photo credit: Medoff

When evaluating the distal radius, the PA view projects the profile of the radial styloid and the articular surface of the distal radius. The carpal facet horizon should be noted at 3-5 mm proximal to distal border of radius. The volar tilt of the distal radius places volar rim more proximally than the dorsal rim. The carpal facet horizon is the projection of the subcortical bone of the volar rim of the lunate facet. This is typically reversed in distal radius fractures due to dorsal tilt of the distal fragment. Therefore, it is important to correlate with a lateral radiograph (Figure 6⁷). Medoff measured average radiographic parameters on the PA view in 40 adults using the central reference point of the ulnar border to measure average radial inclination (23.6 degrees), radial height (11.6 mm), and ulnar variance (-0.6 mm)⁷.

Medoff also advocates for a modified lateral view with the X-ray beam angled 10 degrees proximally in order to provide a more detailed evaluation of the radial articular surface in profile⁷. This is due to the fact that the radial inclination of the ulnar two thirds of the articular surface is 10 degrees to the long axis of the shaft. The lateral view will project the radial styloid as a v-shaped outline superimposed over the lunate. The central axis of lunate will be collinear with volar cortex of radial shaft. The teardrop—the volar rim of lunate facet—will form an angle of an average of 70 degrees with the radial shaft. Finally, the volar tilt is measured by a line perpendicular to the radial shaft axis and a line between the apex of volar rim

and apex of the dorsal rim. Medoff measures an average 11.2 degrees volar tilt⁷.

When assessing radiographs of the hand and wrist, the position of the forearm and hand in space is critical to achieving reliable and reproducible images. Due to the complexity hand and wrist anatomy, evaluation of radiographs can be a daunting task. Beginning with appropriately positioned PA and lateral views will complement rather than confuse diagnostic work up for hand and wrist pain.

References

1. Amrami KK, Moran SL, Berger RA, Ehman EC, Felmlee JP. Imaging the distal radioulnar joint. *Hand Clin* 2010;26:467-475.
2. Daffner RD, Emmerling EW, Buterbaugh GA. Proximal and distal oblique radiography of the wrist: Value in occult injuries. *J Hand Surg Am* 1992;17: 499-503.
3. Epner RA, Bowers WH, Guilford WB. Ulnar variance—the effect of wrist positioning and roentgen filming technique. *J Hand Surg Am* 1982;7:298-305.
4. Gardner-Thorpe D, Giddins GE. A reliable technique for radiographic imaging of the pisotriquetral joint. *J Hand Surg Br* 1999;24:252.
5. Guglielmi G, Peh WCG, Cammisa M. *High Resolution Radiographs of the Hand*. Springer. Berlin, Germany: 2009.
6. Ladd AL. Guest editorial: The Robert's view: a historical and clinical perspective. *Clin Orthop Relat Res* 2014;472:1097-1100.
7. Medoff RJ. Essential radiographic evaluation for distal radius fractures. *Hand Clin* 2005;21:279-288.
8. Papilion JD, DuPuy TE, Aulicino PL, Bergfield TG, Gwathmey FW. Radiographic evaluation of the hook of the hamate: a new technique. *J Hand Surg Am* 1988;13:437-439.