



Height-to-length Ratios to Assess Flexion Deformity in Scaphoid Fractures—a Comparison of Measurement Techniques

Adnan Cheema, MD¹
Paul Niziolek, MD, PhD²
J. Bruce, Kneeland, MD²
David Bozentka, MD¹
David Steinberg, MD¹

¹University of Pennsylvania
Department of Orthopedic Surgery

²University of Pennsylvania
Department of Radiology

Introduction

Scaphoid fractures, particularly those involving the waist, are prone to developing a flexion deformity in the sagittal plane. The distal pole flexes in relation to the proximal pole, which leads to a dorsal “humpback deformity” of the scaphoid. This deformity is important to recognize because it leads to destabilization of the wrist and carpal joints, which most commonly results in dorsal intercalated segment instability (DISI).

Height-to-length ratios can be used to assess the degree of flexion deformity and aid the surgeon in determining when surgery may be indicated. Historically, a height-to-length ratio of greater than 0.65 has been used as a cutoff to intervene surgically. However, there appears to be no consensus on how the height-to-length ratio should be measured. Some authors have tried to use software applications that assess the scaphoid three-dimensionally to obtain a “true” height-to-length ratio. Others have described identifying the sagittal CT cut with the worst deformity and measuring the height-to-length ratio in that plane.

Our null hypothesis for this study is that measuring height-to-length ratios on one sagittal CT cut will not be any more precise than measuring the height-to-length ratios three-dimensionally by taking all CT cuts into account.

Methods

After IRB approval was obtained, 33 patients were identified using an online database of radiology reports. We searched for patients 18 years and older with scaphoid fractures who had had a CT scan of the wrist. We excluded anyone who did not have a CT scan performed before undergoing surgical fixation and those who had any instrumentation in place. In patients with multiple wrist CT scans, we chose the earliest study available in the database. We identified patients in a reverse chronological order beginning from August, 2016 to April, 2011. All enrolled patients were identified from one institution. The CT scans were anonymized and removed of all patient identifiers. Two reformats of each scaphoid CT were created; one in a ‘scaphoid’ axis orientation and one in a ‘wrist axis’ orientation. They were then sent to two clinicians (Rater 1 and Rater 2) for

measurement of height-to-length ratios. Rater 1 was asked to identify the sagittal cut with the largest flexion deformity and record the height-to-length ratio from that cut (Figure 1). Rater 2 was asked to measure the height-to-length ratio three-dimensionally. This was accomplished by first scrolling through all sagittal slices and drawing a line tangential to the two most-volar scaphoid surface curvatures to create the scaphoid long axis. Then, the most-proximal point of the scaphoid was determined similarly by scrolling through all cuts, and a tangential line to this point was drawn perpendicular to the scaphoid long axis. This process was repeated to determine the most distal point of the scaphoid to create a tangential line perpendicular to the long axis. The distance between these two proximal-distal lines determined the scaphoid length. Next, scaphoid height was measured by determining the most dorsal point projected from all slices and drawing a line perpendicular to the initially created long axis line (Figure 2). Each clinician measured the height-to-length ratio once for each axis orientation for a total of two measurements per scaphoid.

Results

The difference between the height-to-length ratio measurements was calculated for each of the 33 scaphoids for Rater 1. The height-to-length ratios varied by a mean of 0.09 and standard deviation of 0.07. The difference between the height-to-length ratio measurements was calculated for each of the 33 scaphoids for Rater 2. The height-to-length ratios varied by a mean of 0.14 and standard deviation of 0.12. Using a t-test, the two means were compared and found to be statistically different with a p value of 0.04. As such, identifying the sagittal cut with the greatest subjective flexion deformity to measure the height-to-length ratio was found to be the more precise method.

Conclusion

Identifying the more precise method to measure flexion deformities in scaphoid fractures has important clinic implications for hand surgeons in that it allows for easier identification of patients who may require surgical intervention. The technique used by Rater 2 is cumbersome and time-consuming,

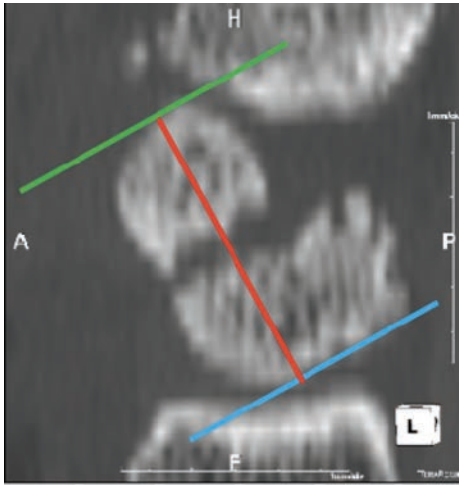


Figure 1. Measurement Technique for Rater 1. The blue line is drawn tangent to the most proximal extent of the scaphoid on this particular cut. The green line is drawn tangent to the most distal extent of the scaphoid on this particular cut. The red line is drawn in line with the long axis of the scaphoid connecting the blue and green lines. This represents the length.

making it less likely to be used in the office setting. Instead, subjectively choosing the sagittal cut with the worst-appearing deformity appears to lead to more precise measurements.

It is important to note that no gold standard exists for measuring flexion deformity in scaphoid fractures. Therefore, the above techniques cannot be compared to the “true” measurement of height-to-length ratios. As such, we cannot comment on the accuracy of the measurement techniques described above. We can only state that one is more precise than the other.

One limitation of this study is that only two measurements were made for each scaphoid. Having more points of reference would allow for more accurate measurement of the precision of each of the above techniques. Another limitation of this study was that each rater did not measure the height-to-length ratios using both techniques, which could potentially introduce observational bias into the analysis.

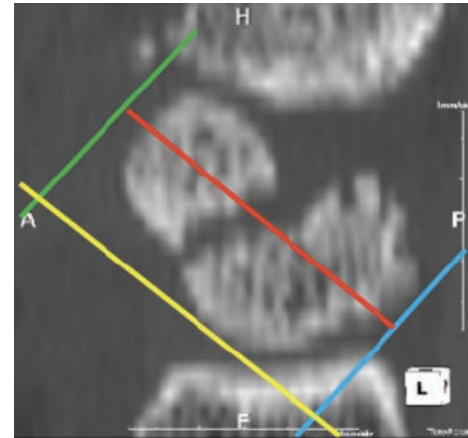


Figure 2. Measurement Technique for Rater 2. After scrolling through all sagittal slices, the yellow line is drawn tangential to the two most-volar scaphoid surfaces (not in the same plane as the cut shown). This designates the scaphoid long axis. The blue line is drawn perpendicular to the yellow line and tangential to the most proximal extent of the scaphoid after scrolling through all cuts. The green line is drawn perpendicular to the yellow line and tangential to the most distal extent of the scaphoid after scrolling through all cuts. The length of the scaphoid is measured by the red line. When compared to Figure 1, one can appreciate that the measurement length is increased and the orientation of the perceived long axis is changed, even though the same sagittal cut is being assessed.

References

1. **PW ten Berg et al.** Quantifying scaphoid malalignment based upon height-to-length ratios obtained by 3-dimensional computed tomography. *J Hand Surg Am.* 2015 Jan;40(1):67-73.
2. **Bain et al.** Measurement of the scaphoid humpback deformity using longitudinal computed tomography: intra- and interobserver variability using various measurement techniques. *J Hand Surg Am.* 1998 Jan;23(1):76-81.
3. **Ring et al.** Both Scanning Plane and Observer Affect Measurements of Scaphoid Deformity. *J Hand Surg Am.* 2005 July; 30(4): 696-701.
4. **Nakamura et al.** Analysis of Scaphoid Fracture Displacement by Three-Dimensional Computer Tomography. *J Hand Surg Am.* May 1991; 16(3): 485-492.
5. **Sanders, William E.** Evaluation of the Humpback Scaphoid by Computed Tomography in the Longitudinal Axial Plane of the Scaphoid. *J Hand Surg Am.* March 1998; 13(2):182-187