



U·P·O·J

Current Concepts in Management of Unstable Slipped Capital Femoral Epiphysis

Brendan Striano, BA¹

Taylor Jackson, BA¹

Daniel Miller, MD¹

Wudbhav Sankar, MD¹

¹Division of Orthopaedic Surgery, The Children's Hospital of Philadelphia, 3400 Civic Center Boulevard, 2nd Floor Wood Building, Philadelphia, Pennsylvania, USA 19104

Introduction

Slipped capital femoral epiphysis (SCFE) is the most common hip condition in the adolescent population and represents mechanical failure of the physis, which allows displacement of the proximal femoral epiphysis relative to the metaphysis¹. As described by Loder, SCFE can be classified as stable or an unstable based on clinical presentation, with unstable SCFE being painful enough to prevent ambulation, even with crutches or other walking aids². The most worrisome outcome with SCFE is osteonecrosis of the femoral head³, for which Loder's classification is prognostic. Stable slips typically have good prognosis with essentially a 0% risk of osteonecrosis, while unstable slips have been reported to develop AVN in 0%-58% of cases, with an overall rate thought to be 24%^{4,7}. Osteonecrosis is devastating because it results in immediate disability, loss of function, and places patients at high risk for premature osteoarthritis^{5,7-9}.

There is currently little consensus on the management for unstable SCFE, with significant variation in surgeon preference for management^{10,11}. Treatment options vary in several realms, including timing of treatment, choosing in-situ fixation v. reduction, number of implants, and whether or not to perform a capsulotomy. Because vast treatment options exist and providers lack consensus, it is worthwhile to review recent research and current concepts of the treatment of unstable SCFE.

Operative Considerations

Timing of Surgery

When treating an unstable SCFE, timing has long been considered an important factor. Despite considerable research, there is still some controversy about the optimal timing of SCFE fixation¹²⁻¹⁴. Chen et al. demonstrated good outcomes when fixation was performed urgently, within 12-24 hours of presentation¹³. Similarly, Parsch et al. had excellent results in patients treated within 24 hours of the onset of pain¹⁵. Other studies have suggested that timing may not be as significant⁸. Interestingly, a European study suggested "windows" of opportunity. Kalogrianitis et al. recommended treating patients within 24 hours if possible or waiting for almost a week to allow an

"inflammatory effusion" to resolve¹⁶. A systematic review by Alshryda et al. showed that timing of surgery was an independent predictor of AVN, but also supported the concept of "windows" of opportunity¹⁷. In spite of this data, most centers in the United States favor urgent treatment of unstable slips whenever possible.

Role of capsular decompression

The periosteal tearing associated with an unstable SCFE often results in considerable intra-capsular hematoma. From the femoral neck fracture literature, it is known that intra-capsular hematoma can increase capsular pressure and tamponade the epiphyseal vasculature^{18, 19}. Herrera-Soto et al. demonstrated that attempted closed reduction can contribute to increased capsular pressure to levels above those seen in myofascial compartment syndrome²⁰. Therefore, with an unstable SCFE, surgeons should consider capsular decompression with either needle decompression, percutaneous capsulotomy, or formal open capsulotomy³³.

"In-situ" Fixation vs. Closed reduction and fixation

When treating an unstable SCFE, most surgeons perform "in-situ" fixation, which may be more accurately termed a positional reduction, or attempt a formal, purposeful closed reduction⁴. These options offer the benefit of familiarity for nearly all orthopaedists, regardless of training, and allow for prompt stabilization²¹. In-situ fixation has long been a standard procedure, with low rates of osteonecrosis (9-12%) and good initial clinical outcomes^{12,22}. However, recent data has demonstrated that for some unstable SCFEs, in-situ fixation may have poor long-term, patient reported functional outcomes, due to high rates of residual deformity^{15,23}. These findings, which may previously have been underappreciated, are an expected consequence of in-situ fixation because there is no attempt at reducing the deformity. Driven by these recent data, there has been renewed interest in achieving more anatomic reduction. Historically, purposeful closed reduction has been discouraged because a partial or complete purposeful reduction has been associated with an increased incidence of AVN^{5,14,24}. However, recent advances in the ability to assess femoral head perfusion have led to renewed interest in purposeful reduction.

Epiphyseal Perfusion Monitoring

One of these most significant recent advances has been the development of intra-operative monitoring techniques, which may allow improvements in both closed and open treatment options^{3,4,7}. Assessment of blood flow may help identify patients at high risk for osteonecrosis and allow for early intervention before hip deformity occurs⁹. Options include assessing epiphyseal bleeding with drilling, laser flowmetry probe, and using an intracranial pressure (ICP) catheter^{3,4,7}. One significant advantage of ICP probe monitoring is that it can be done percutaneously⁴. A recent study by Schrader et al. described a technique of perfusion monitoring using an ICP probe inserted through a percutaneously placed cannulated screw (Figure 1). The series included 13 patients with unstable SCFE. Initially, flow was identified in seven patients, and no perfusion was detected in the remaining six. Perfusion was restored in all six following percutaneous capsular decompression. At two years follow-up, there was no radiographic evidence of AVN and no complications from use of ICP monitoring³.

Open reduction and internal fixation

Parsch et al. described a technique which consists of an urgent open approach, capsulotomy, and direct visualization of the femoral neck, followed by gentle, finger-tip reduction^{12, 21}. The proximal femur is exposed through an anterolateral Watson-Jones approach with a longitudinal capsulotomy, which also allows for evacuation of the joint effusion. A Kirschner wire is then inserted through lateral cortex and advanced to the metaphyseal edge of the slip. The surgeon then palpates the gap between the metaphysis and epiphysis, keeping a finger on the femoral head to allow for a more controlled, gentle reduction of the acute portion of the slip. Once adequate reduction is achieved, the multiple Kirschner wires are advanced into the epiphysis to achieve fixation.

The strengths of this approach are the timeliness of treatment, evacuation of the intraarticular hematoma through capsulotomy, and the gentleness of partial finger-tip reduction^{12, 21}. In a series of 64 slips treated with this technique, there were excellent outcome scores and extremely low rates of AVN, below 5%^{12, 21}.

Modified Dunn

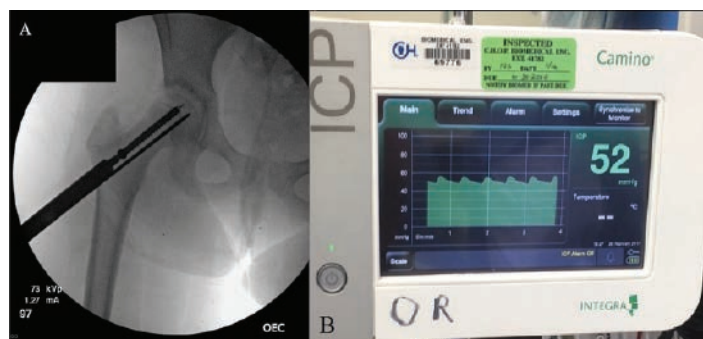


Figure 1. (A) Representative image of intracranial pressure probe in femoral epiphysis monitoring perfusion (B) Perfusion monitoring system demonstrating waveform and pulse pressure.

Recently, the so-called modified Dunn procedure has received much attention. This is an open capital realignment performed through a surgical dislocation approach, allowing for identification and preservation of the vascular supply, which allows for a controlled and anatomic reduction of the femoral epiphysis⁷. While the modified Dunn can restore near normal anatomy, the procedure is technically demanding and requires specialized training, which inhibits its widespread utilization. Despite these limitations, the procedure has rapidly gained popularity at several centers. Ziebarth et al. reported very low complication rates in 40 patients (12 with unstable SCFE), with no osteonecrosis and 2.5% residual impingement after an average follow-up of 54 months⁷. With a mean follow-up of 12 years, Ziebarth et al. reported improved radiographic alignment, but follow-up operative intervention for impingement was necessary in 14% of hips. Even with such long follow-up, there were still no cases of osteonecrosis, however, only 5 of these patients presented with unstable SCFE²⁵. Sankar et al., in a multicenter series, reported on twenty-seven patients, and found a 27% rate of osteonecrosis after an average follow-up of 22.3 months⁴. The wide range in reported outcomes and complication rates may in part be related to the technical difficulty of the procedure. Subsequent studies have demonstrated that surgeon volume and experience play a significant role in complication rate. Reported rates range from 17% in the most experienced to 50-100% in the least experienced surgeons²⁶.

Author's Preferred Technique

With expanding options for treatment and perfusion monitoring, we find it important to have a treatment algorithm for unstable SCFE that incorporates information about epiphyseal perfusion, patient preference, and surgeon comfort level (Figure 1). At our institution, all unstable SCFEs are treated urgently. For mild, unstable slips, gentle positional reduction and fixation with two 6.5mm cannulated screws is an excellent treatment option. Femoral head perfusion is monitored using an ICP catheter through the cannulated screw as described by Schrader³. If after fixation, the epiphysis is ischemic, a percutaneous capsulotomy is performed. If monitored perfusion still remains absent, a formal open arthrotomy is performed. Finally, if perfusion continues to be impaired, consideration is given for removing the internal fixation and reattempting closed reduction versus performing an emergent modified Dunn procedure (Figure 2).

If the slip is moderate to severe at initial presentation, there is consideration of bypassing in-situ fixation and proceeding directly with a modified Dunn procedure. This route is considered only when a qualified hip specialist is available. It is important that the patient and family receive a full explanation of the risks and benefits of the more invasive modified Dunn procedure to allow for shared decision-making.

While at our institution the modified Dunn is the treatment of choice for severe SCFE or those with no measurable perfusion, it should be emphasized that other options, such as "in-situ" fixation and the Parsch method are certainly worthwhile depending on surgeon comfort level. The Parsch

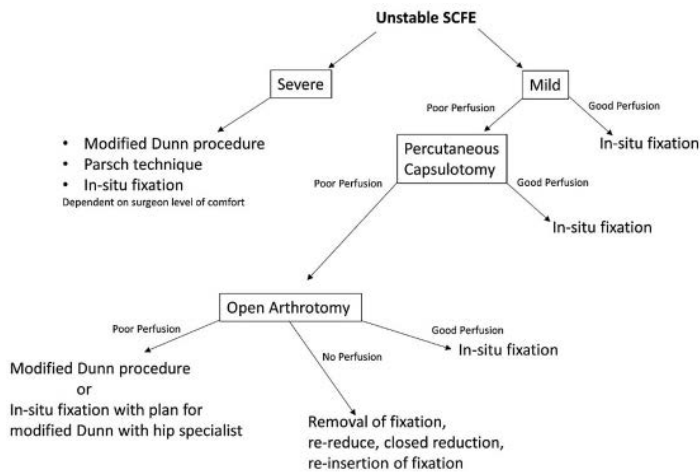


Figure 2. Decision making algorithm for treatment of unstable slipped capital femoral epiphysis. Perfusion is monitored with intra-cranial perfusion probe, as described by Schrader et al. This algorithm reflects the practice at our institution based on physician level of comfort, familiarity, and institutional experience.

method, in particular, can be performed safely in most centers and has very low rates of reported AVN¹².

Discussion

Osteonecrosis is the most serious consequences of an unstable SCFE^{6,21}. It places the patient at risk for hip deformity, hip osteoarthritis, and need for total hip arthroplasty later in life^{4,5,7}. Furthermore, patients who develop osteonecrosis have worse functional and quality of life outcomes⁴. Therefore, minimizing the risk of AVN is the top priority in treatment of unstable SCFE. Recent systematic review found the overall rate of osteonecrosis after unstable SCFE to be 24%^{4,7}.

The etiology of AVN in unstable slips is thought to be tamponade within the joint capsule from hematoma and/or kinking or tearing of the epiphyseal vessels²⁶. Restoring blood flow may be achieved by gentle reduction and decompression of the joint capsule hematoma^{3,2,20,21,26}. The use of intraoperative epiphyseal perfusion monitoring can aid in detecting patients with reduced blood flow and potentially allow surgical interventions to improve femoral head perfusion. This advance, along with the development of the modified Dunn procedure, has increased our armamentarium for treating unstable SCFE. Although osteonecrosis may never be a “never event” following unstable slips, an appropriate algorithmic approach considering timing of surgery, decompression of the hip capsule, intraoperative perfusion monitoring, and a carefully chosen surgical technique, may mitigate the risk of osteonecrosis and optimize the long-term outcomes of this challenging condition.

References

1. Lehmann CL, Arons RR, Loder RT, Vitale MG. The epidemiology of slipped capital femoral epiphysis: an update. *J Pediatr Orthop*. 2006;26(3):286-90.
2. Loder RT, Richards BS, Shapiro PS, Reznick LR, Aronson DD. Acute slipped capital femoral

epiphysis: the importance of physeal stability. *J Bone Joint Surg Am*. 1993;75(8):1134-40.

3. Schrader T, Jones CR, Kaufman AM, Herzog MM. Intraoperative Monitoring of Epiphyseal Perfusion in Slipped Capital Femoral Epiphysis. *J Bone Joint Surg Am*. 2016;98(12):1030-40.
4. Sankar WN, Vanderhave KL, Matheny T, Herrera-Soto JA, Karlen JW. The modified Dunn procedure for unstable slipped capital femoral epiphysis: a multicenter perspective. *J Bone Joint Surg Am*. 2013;95(7):585-91.
5. Tokmakova KP, Stanton RP, Mason DE. Factors influencing the development of osteonecrosis in patients treated for slipped capital femoral epiphysis. *J Bone Joint Surg Am*. 2003;85-A(5):798-801.
6. Zaltz I, Baca G, Clohisy JC. Unstable SCFE: review of treatment modalities and prevalence of osteonecrosis. *Clin Orthop Relat Res*. 2013;471(7):2192-8.
7. Ziebarth K, Zilkens C, Spencer S, Leunig M, Ganz R, Kim YJ. Capital realignment for moderate and severe SCFE using a modified Dunn procedure. *Clin Orthop Relat Res*. 2009;467(3):704-16.
8. Sankar WN, McPartland TG, Millis MB, Kim YJ. The unstable slipped capital femoral epiphysis: risk factors for osteonecrosis. *J Pediatr Orthop*. 2010;30(6):544-8.
9. Novais EN, Sink EL, Kestel LA, Carry PM, Abdo JC, Heare TC. Is Assessment of Femoral Head Perfusion During Modified Dunn for Unstable Slipped Capital Femoral Epiphysis an Accurate Indicator of Osteonecrosis? *Clin Orthop Relat Res*. 2016;474(8):1837-44.
10. Thawrani DP, Feldman DS, Sala DA. Current Practice in the Management of Slipped Capital Femoral Epiphysis. *J Pediatr Orthop*. 2016;36(3):e27-37.
11. Jamjoom BA, Butler D, Thomas S, Ramachandran M, Cooke S. Opinion survey of members of British Society of Children's Orthopaedic Surgery related to specific case scenarios in slipped capital femoral epiphysis. *J Pediatr Orthop B*. 2017.
12. Parsch K, Weller S, Parsch D. Open reduction and smooth Kirschner wire fixation for unstable slipped capital femoral epiphysis. *J Pediatr Orthop*. 2009;29(1):1-8.
13. Chen RC, Schoenecker PL, Dobbs MB, Luhmann SJ, Szymanski DA, Gordon JE. Urgent reduction, fixation, and arthrotomy for unstable slipped capital femoral epiphysis. *J Pediatr Orthop*. 2009;29(7):687-94.
14. Casey BH, Hamilton HW, Bobechko WP. Reduction of acutely slipped upper femoral epiphysis. *J Bone Joint Surg Br*. 1972;54(4):607-14.
15. Akiyama M, Nakashima Y, Kitano T, Nakamura T, Takamura K, Kohno Y, et al. Remodelling of femoral head-neck junction in slipped capital femoral epiphysis: a multicentre study. *Int Orthop*. 2013;37(12):2331-6.
16. Kalogrianitis S, Tan CK, Kemp GJ, Bass A, Bruce C. Does unstable slipped capital femoral epiphysis require urgent stabilization? *J Pediatr Orthop B*. 2007;16(1):6-9.
17. Alshryda S, Tsang K, Chytas A, Chaudhry M, Sacchi K, Ahmad M, et al. Evidence based treatment for unstable slipped upper femoral epiphysis: Systematic review and exploratory patient level analysis. *Surgeon*. 2016.
18. Maruenda JI, Barrios C, Gomar-Sancho F. Intracapsular hip pressure after femoral neck fracture. *Clin Orthop Relat Res*. 1997(340):172-80.
19. Beck M, Siebenrock KA, Affolter B, Notzli H, Parvizi J, Ganz R. Increased intraarticular pressure reduces blood flow to the femoral head. *Clin Orthop Relat Res*. 2004(424):149-52.
20. Herrera-Soto JA, Duffy MF, Birnbaum MA, Vander Have KL. Increased intracapsular pressures after unstable slipped capital femoral epiphysis. *J Pediatr Orthop*. 2008;28(7):723-8.
21. Wenger DR, Bomar JD. Acute, unstable, slipped capital femoral epiphysis: is there a role for in situ fixation? *J Pediatr Orthop*. 2014;34 Suppl 1:S11-7.
22. Ziebarth K, Leunig M, Slongo T, Kim YJ, Ganz R. Slipped capital femoral epiphysis: relevant pathophysiological findings with open surgery. *Clin Orthop Relat Res*. 2013;471(7):2156-62.
23. Fraitl CR, Kafer W, Nelitz M, Reichel H. Radiological evidence of femoroacetabular impingement in mild slipped capital femoral epiphysis: a mean follow-up of 14.4 years after pinning in situ. *J Bone Joint Surg Br*. 2007;89(12):1592-6.
24. Kitano T, Nakagawa K, Wada M, Moriyama M. Closed reduction of slipped capital femoral epiphysis: high-risk factor for avascular necrosis. *J Pediatr Orthop B*. 2015;24(4):281-5.
25. Ziebarth K, Milosevic M, Lerch TD, Steppacher SD, Slongo T, Siebenrock KA. High Survivorship and Little Osteoarthritis at 10-year Followup in SCFE Patients Treated With a Modified Dunn Procedure. *Clin Orthop Relat Res*. 2017;475(4):1212-28.
26. Maeda S, Kita A, Funayama K, Kokubun S. Vascular supply to slipped capital femoral epiphysis. *J Pediatr Orthop*. 2001;21(5):664-7.