



# Hip Pain: A Case Report of Diagnosing Femoroacetabular Impingement in an Adolescent Athlete

Jermonte Lowe, BS  
Julien Aoyama, BA  
Nancy Chauvin, MD  
Lawrence Wells, MD

## Introduction

Femoroacetabular impingement (FAI) is characterized by abnormal morphology of the proximal femur and/or acetabulum. FAI is a condition of abnormal contact that may arise as a result of either abnormal morphologic features involving the proximal femur and/or the acetabulum. It may also occur from excessive and supraphysiologic hip ROM leading to impingement.<sup>1</sup> Although there are several adult-specific reports of FAI in the literature, research involving skeletally immature subjects is sparse and there is no consensus on how to reach a definitive diagnosis for FAI. Consequently, it is not uncommon for pediatricians and pediatric radiologists to misdiagnose FAI as hip or groin strains, which can negatively affect prognosis. Here we characterize an FAI diagnosis in a 15-year-old female athlete and the management outcome.

## Case Information

A 15-year-old female ice hockey and field hockey goalie presented to our hospital with a history of 4-week right hip pain after initial evaluation and conservative treatment by an outside orthopedic surgeon. Complaints of sharp pain in her right hip began when she was sprinting during field hockey practice. She was told she may have a hip labrum tear by an outside orthopedic surgeon and was prescribed 3 weeks of crutches and activity restrictions. After no significant improvement in right hip pain with activity modifications, she presented to our hospital for further evaluation and treatment. She reported her symptoms improved with rest but worsened anytime she moved her hips. She noted her right hip pain had not improved significantly with acetaminophen and crutch ambulation as prescribed. She also noted previous IT band injury to the right side but otherwise no significant past medical history.

Standing evaluation revealed no asymmetry in iliac crest height or scoliosis. Mild palpation tenderness was present around the right hip as well as comparatively reduced external rotation ( $45^\circ$  on R,  $60^\circ$  on L), and abduction ( $40^\circ$  on R,  $70^\circ$  on L) of the right hip. Strength was 5/5 bilaterally for all muscles of the hips and pelvis. Resistance tests elicited no pain and she was able to perform straight leg raises without

issue. FABER, Thomas, and Ely special tests were negative bilaterally. However, flexion, adduction and internal rotation impingement and Ober tests were positive on the right hip.

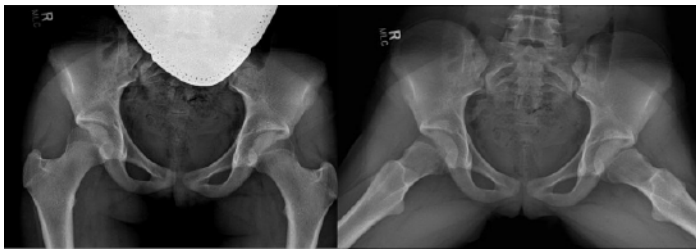Anterior-posterior and frog lateral radiographs of the hip and pelvis were obtained and initially interpreted as normal by the radiologist. (Figure 1) However, upon evaluation by our orthopedic surgeon, mild bilateral CAM deformities of the femoral necks were seen. (Figure 2) Alpha angles measured on the frog lateral radiographs were found to be  $73^\circ$  on the right and  $68^\circ$  on the left. A follow-up direct MR arthrogram of the right hip was performed which demonstrated a labral tear along the mid-portion of the superior labrum. (Figure 3) Axial oblique MR imaging and radial reformatted imaging showed a small osseous bump along the anterolateral aspect of the proximal femoral metaphysis. There was physiologic physeal closure within the central portion of the proximal femoral physis, which ruled out a possible slipped capital femoral epiphysis.

## Management

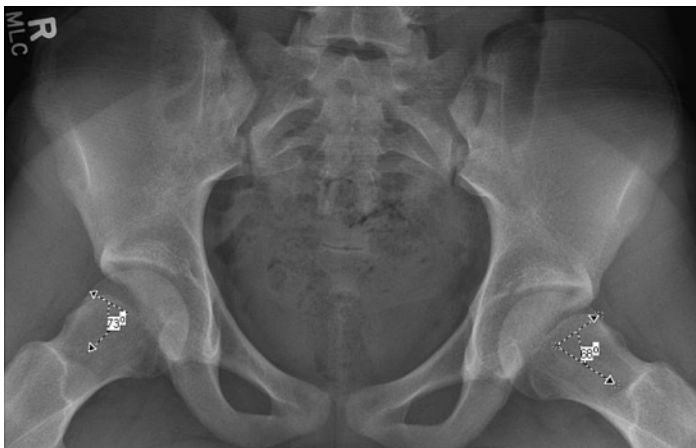We offered arthroscopic labral repair and osteoplasty of the bilateral FAI CAM deformities to the patient but she elected to receive treatment at an outside hospital. There she was treated with bilateral open osteoplasties of the femoral necks and an open labral repair of the right hip. Postoperatively she did well with no complaints of pain at either hip at the 2-month mark when she returned to see us. However, she reported she had given up ice hockey and would continue to play field hockey only.

## Discussion

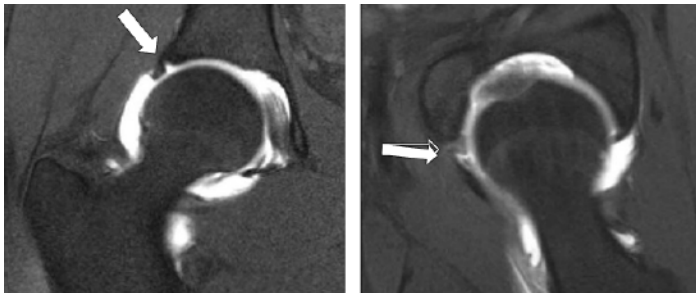
Young athletes repetitively flexing and/or internally rotating the hip joint with dance, lacrosse, field or ice hockey (especially goalies) are more susceptible to hip labral tears. Hockey players in particular tend to develop impingement at a much higher rate than other athletes. One study comparing hockey players and skiers found that CAM impingement affected 79% of ice hockey players versus only 40% of skiers.<sup>2</sup> When improperly treated, FAI may lead to persistent symptoms and early-onset osteoarthritis of the hip.<sup>1</sup> Surgery, including hip arthroscopy, surgical dislocation,



**Figure 1.** Anterior-posterior and frog lateral radiographs of the bilateral hips and pelvis. Mild CAM deformities can be seen on both femoral necks in the lateral view.



**Figure 2.** Frog lateral radiographs of the bilateral hips and pelvis with CAM deformities on both femoral necks (white asterisks). Alpha angles were measured and found to be 73 and 68 degrees for the right and left hips respectively.



**Figure 3.** T1-weighted coronal (left) and axial (right) MR images of the right hip showing the superior labral tear (solid white arrow).

and osteochondroplasty are safe and successful treatment options for abnormal hip morphologies, and without surgical intervention CAM lesions may significantly reduce the length of an athlete's career and increase their risk for osteoarthritis.<sup>3</sup>

Many cases of FAI are underreported because they are misdiagnosed as hip or groin strains.<sup>2</sup> Fortunately, the physical

findings of FAI are specific. Anterior FAI occurs when the hip is flexed and internally rotated, bringing the femoral neck against the anterior acetabulum and labrum. Posterior FAI occurs when the hip is extended and externally rotated. Given the patient with anterior or posterior hip pain, these maneuvers are crucial to progressing towards an appropriate diagnosis.<sup>4</sup>

Classical radiographic findings of CAM impingement include a pistol grip deformity with bony prominence at the anterolateral femoral head and neck junction on lateral radiograph of the hip.<sup>5</sup> Pincer impingement is seen in entities that result in a closer approximation of the femoral head-neck junction and the lateral acetabular rim (i.e., coxa vara, acetabular protrusion, retrotorsion of femoral head, coxa magna, ossification of acetabular rim, acetabular retroversion).<sup>5</sup>

Cross-sectional MR or CT imaging may also confirm FAI. Both exams are sufficient for measuring alpha angles of the hip joint. Alpha angles greater than 50 degrees are widely accepted for diagnosing CAM impingement. MR imaging is especially effective in discerning acetabular labral damage from impingement of the acetabulum and femoral head/neck junction, by illustrating increased labral signal on fluid sensitive images that extends to the articular surface.<sup>5</sup>

Differential diagnoses in adolescents include hip strain, overuse injury, and slipped capital femoral epiphysis (SCFE). Radiographic workup can exclude SCFE and confirm FAI.

## Conclusion

In summary, the recognition of FAI in adolescent athletes is significant and often overlooked. We illustrate the history, physical and radiographic findings of FAI in a young athlete, including surgical results. Armed with the proper diagnosis and treatment, this patient was allowed to return to sport and pursue her aspiration to play field hockey in college.

## References

1. Ganz R, Parvizi J, Beck M, Leunig M, Notzli H, Siebenrock KA. Femoroacetabular impingement: a cause for osteoarthritis of the hip. *Clin Orthop Relat Res.* 2003;417:112-20.
2. Philippon MJ, Ho CP, Briggs KK, Stull J, LaPrade RF. Prevalence of increased alpha angles as a measure of cam-type femoroacetabular impingement in youth ice hockey players. *Am J Sports Med.* 2013;41(6):1357-62.
3. Ramachandran M, Azegami S, Hosalkar HS. Current concepts in the treatment of adolescent femoroacetabular impingement. *J Child Orthop.* 2013;7(2):79-90.
4. Grant AD, Sala DA, Schwarzkopf R. Femoro-acetabular impingement: the diagnosis-a review. *J Child Orthop.* 2012;6(1):1-12.
5. Beall DP, Sweet CF, Martin HD, Lastine CL, Grayson DE, Ly JO, et al. Imaging findings of femoroacetabular impingement syndrome. *Skeletal Radiol.* 2005;34(11):691-701.