

Growth Modulation for Idiopathic Scoliosis with an Anterior Tether—Operative Technique

Susan Nelson, MD, MPH
Todd Blumberg, MD
Andrew Gambone, MD
Daniel Miller, MD
Patrick Cahill, MD

Introduction and Background

Adolescent idiopathic scoliosis (AIS) is a three-dimensional spinal deformity consisting of alterations in the coronal and sagittal plane as well as axial rotation. Treatment options include observation, bracing, or surgery depending on patient characteristics, curve magnitude, and skeletal maturity. Deformity correction and fusion is currently the gold standard for surgical treatment of AIS¹. Recent advances in treatment of AIS include fusion-less strategies that harness spine growth to guide the deformity similar to asymmetric tethering of the physis to correct long bone deformities. The advantages of fusion-less technique are preserved spinal motion and future growth. Staples have been used to modulate spine growth in idiopathic scoliosis^{2,3} and recently flexible tethering has been used^{1,4,5}. A flexible anterolateral tether placed thoracoscopically allows for dynamic compression to modulate growth, while minimizing effects on disc health and motion⁶.

Pre-operative Evaluation and Indications

Indications for anterior tethering are being established for this innovative approach to managing idiopathic scoliosis. Current relative indications include: age >9 years, >2 years of growth remaining, thoracic major scoliosis, Cobb angle 40-65 degrees, non-structural compensatory curves, Cobb angle between vertebrae T5 and L1⁵. Contraindications include congenital malformations, patients who would not tolerate a thoracoscopic approach, skeletal maturity, and patients with vertebrae too small in the thoracic region to accommodate anterior instrumentation. All patients should have pre-operative physical examination and work up as appropriate for any patient with AIS. This includes neurologic examination, assessment of curve flexibility clinically and radiographically, and pre-operative MRI evaluation for neuraxial pathology. Levels selected for tethering are within the measured Cobb angle. Although there is not a precise method to determine correction, initial correction should be planned based on growth remaining.

Procedure

The presence or availability of general surgeon for the thoracoscopic approach may be required

based on the primary surgeon's experience and comfort. Thoracoscopic exposure is facilitated by single lung ventilation anesthesia. After induction of anesthesia the patient is positioned on a radiolucent table in left lateral decubitus for a typical right thoracic curve. Using fluoroscopy, the upper and lower instrumented vertebrae are marked, as is a line over and parallel to the vertebral bodies in the sagittal plane (Fig. 1). Depending on surgeon preference, the coronal trajectory of each level may also be marked. Wide prep and draping of the chest is mandatory in case an extensile approach is required.

Anterior portals are established first in the anterior axillary line. A small amount of local anesthetic is infiltrated and incision is made with a 15 blade followed by blunt dissection with a hemostat for placement of a 5mm viewing cannula. The length of planned instrumentation is divided into quarters with the proximal anterior portal made at the bottom of the top 25% (Figure 1). A second anterior portal can be placed three interspaces distal to this. Posterior trajectory is maintained during entry into the thoracic cavity coming over the rib with the trocar. The chest cavity is insufflated with CO₂ and a 30 degree endoscope is placed. The lung is gently retracted using an endoscopic peanut until completely deflated. Levels are confirmed with fluoroscopy. The parietal pleura overlying the spine is divided and the segmental vessels cauterized using a harmonic scalpel/coagulation. Maintaining hemostasis is essential for adequate visualization. With the parietal pleura retracted a sponge may be placed between the spine and the esophagus and great vessels. This facilitates exposure and protects these structures.

Posterior portals are then established along the previously marked line to facilitate direct lateral trajectory to the spine for instrumentation. 15mm cannulas are used. Local anesthetic



Figure 1. Marking of levels is done prior to procedure start under fluorosc, guidance. Anterior portals are established in the anterior axillary line.

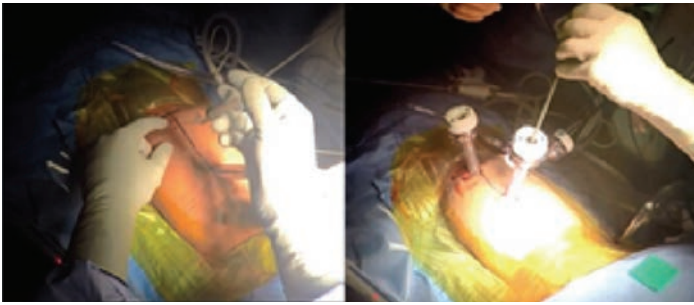

Figure 2. Posterior portals are established along previously marked area. Local anesthetic is infiltrated and can help localize.

infiltration into the intended interspace can be helpful and the needle used to directly visualize the trajectory (Figure 2). Usually two to three levels can be instrumented through one interspace portal. The number of posterior portals will be dictated by the number of instrumented levels planned. Levels are instrumented sequentially distally to proximally starting with pronged centering staples impacted into the mid portion of the lateral vertebral bodies. Bone wax is placed into the staple to maintain hemostasis and placement checked with fluoroscopy. A tap is used through the staple and trajectory confirmed fluoroscopically. The far cortex should be carefully penetrated for bicortical fixation. Screws are placed followed by the flexible tether which is manipulated into the tulips and secured with set screws. An external tensioning device is used to take any slack out of the tether and initiate correction before final tightening (Figure 3).

Once fluoroscopy confirms adequate initial correction the tether can be trimmed with the harmonic scalpel. Local anesthetic is injected posteriorly at the level of the transverse process at each level under direct thoracoscopic visualization to ensure the pleura is not penetrated. A chest tube is placed and portal sites are closed in layers.

Postoperative Protocol

Chest tube suction is set to -20cm H₂O. Output may initially be high due to any irrigation used intraoperatively. The chest tube is typically discontinued when output is <200cc/24hr.

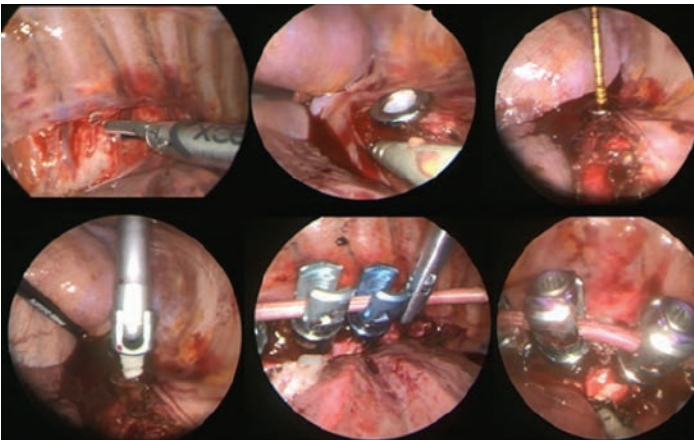


Figure 3. The segmental vessels are cauterized with the harmonic scalpel prior to instrumentation. A pronged staple has been placed and filled with bone wax followed by tapping and screw placement. Placement of the flexible tether and final position.

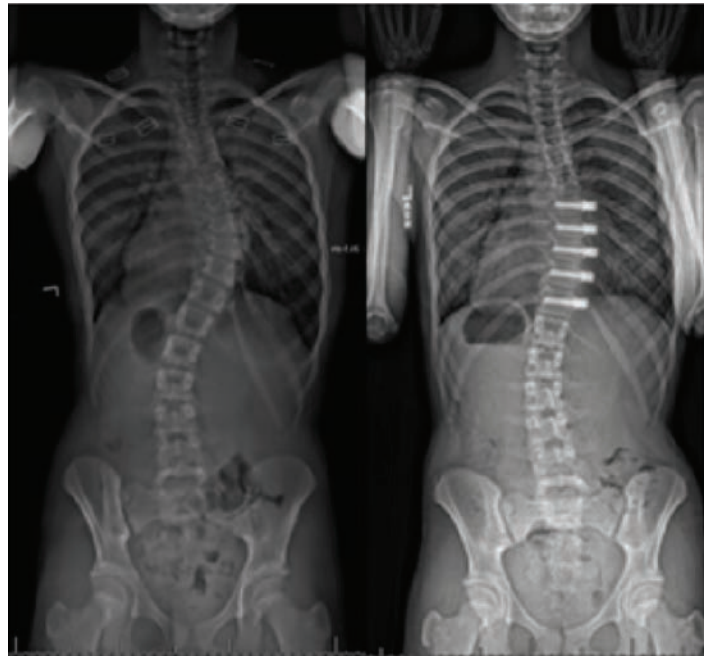


Figure 4. Pre- and post-standing radiographs showing instrumentation and initial correction.

Early mobilization and incentive spirometry are encouraged. The patient is seen 6 weeks post operatively with PA and lateral scoliosis radiographs (Figure 4).

Activity is advanced at this point. Patients are followed subsequently at 3 months and then every 6 months to monitor correction until skeletal maturity. If signs of overcorrection are noticed on follow-up imaging, the tether can be cut in a minor procedure to prevent progression.

Discussion

Anterior tethering for idiopathic scoliosis has the potential to harness growth for curve correction thus maintaining spine flexibility, allowing growth, and saving the patient from a larger spinal fusion operation. Indications for this technique are evolving and overcorrection may occur. However, in the appropriately selected patient growth modulation can successfully correct scoliosis while avoiding spinal fusion.

References

1. Newton PO, Upasani VV, Farnsworth CL, Oka R, Chambers RC, Dwek J, et al. Spinal growth modulation with use of a tether in an immature porcine model. *J Bone Joint Surg Am.* 2008;90(12):2695-706.
2. Betz RR, Ranade A, Samdani AF, Chafetz R, D'Andrea LP, Gaughan JP, et al. Vertebral body stapling: a fusionless treatment option for a growing child with moderate idiopathic scoliosis. *Spine (Phila Pa 1976).* 2010;35(2):169-76.
3. Lavelle WF, Samdani AF, Cahill PJ, Betz RR. Clinical outcomes of nitinol staples for preventing curve progression in idiopathic scoliosis. *J Pediatr Orthop.* 2011;31(1 Suppl):S107-13.
4. Crawford CH, 3rd, Lenke LG. Growth modulation by means of anterior tethering resulting in progressive correction of juvenile idiopathic scoliosis: a case report. *J Bone Joint Surg Am.* 2010;92(1):202-9.
5. Newton PO. Anterior Tether for Growth Modulation. In: Skaggs DL, Kocher MS, editors. *Master Techniques in Orthopaedic Surgery Pediatrics.* 2nd ed. Philadelphia Wolters Kluwer 2016.
6. Wang DL, Jiang SD, Dai LY. Biologic response of the intervertebral disc to static and dynamic compression in vitro. *Spine (Phila Pa 1976).* 2007;32(23):2521-8.