

# Single Leg Spica Casting for Low Energy Pediatric Femur Fractures—Operative Technique

Daniel Miller, MD  
 Susan Nelson, MD, MPH  
 Todd Blumberg, MD  
 Andrew Gambone, MD  
 Joseph Monteleone

<sup>1</sup>Division of Orthopaedic Surgery  
 The Children's Hospital of Philadelphia  
 Philadelphia, Pennsylvania

## Introduction

Femoral shaft fractures are common pediatric injuries, with treatment strategies depending on patient age, weight, skeletal maturity, fracture location, comminution, soft tissue integrity, and associated injuries. The American Academy of Orthopaedic Surgeons (AAOS) Clinical Practice Guidelines suggest early spica casting or traction with delayed spica casting for children aged 6 months to 5 years with a diaphyseal femur fracture with <2 cm of shortening<sup>1</sup>. Historically, spica casting for pediatric femoral shaft fractures consisted of a two or one and a half leg spica with the injured leg in 90° of hip flexion and 90° of knee flexion<sup>2,3</sup>. While this is associated with good long term results, there is a significant burden of care on the patient, family, and community<sup>4</sup>. The single leg “walking spica” is safe and efficacious for treatment of low energy pediatric femoral shaft fractures<sup>2,3,5</sup> that decreases burden of care for the patient and family by facilitating safe mobilization with the well leg free<sup>3,5</sup>. Because of this, single leg spica casting has become the preferred technique at our institution. The purpose of this article is to describe this technique for the treatment of low energy pediatric femoral shaft fracture.

## Preoperative Evaluation and Indications

Single leg spica casting is indicated in patients aged 6 months—4 years after low energy trauma (e.g. falling off a bed). Contraindications include high energy injury patterns suggested by significant fracture comminution, fracture shortening > 2 cm, or polytrauma.

All patients should undergo a history and physical and screened for concomitant


injuries. Children less than 3 years of age should be evaluated for non-accidental trauma, particularly in those patients who are not yet walking. Families should be warned about the potential for complications including fracture displacement, skin related issues, and need for wedging or additional procedures.

## Procedure

Closed reduction and spica casting can be performed in the operating room or emergency department provided that appropriate personnel, materials, and sedation are available (Figure 1)<sup>6</sup>. Muscle relaxation may be requested to facilitate closed reduction. We suggest at least two skilled personnel in addition to the surgeon be present to facilitate cast application. A time out should be performed as per institutional protocol.

After induction of anesthesia, an appropriately sized Gore-tex Pantaloon (W. R. Gore and Associates, Inc., Flagstaff, AZ) is applied to act as a waterproof barrier in the event of soiling. Excess liner is removed from the patient's well leg. Layers of six inch stockinette or folded surgical towels are placed between the patient's abdomen and liner to provide room for abdominal expansion following cast application. While the anesthesiologist controls the airway, the child is carefully lifted onto a spica casting table.

The proximal (box) portion of the spica table should end on the mid thoracic spine, at approximately T7, fully supporting the shoulders. The well-padded distal post of the spica table should be adjusted so that it rests snugly against the patient's perineum, supporting the sacrum. The patient's arms may be secured to the side



**Figure 1.** (A) Supplies include 2 and 3 inch fiberglass cast tape, soft roll, and stockinette folded to be placed on the stomach (B) One variation of hip spica table.

or overhead with cast padding or held in place by an assistant depending on the configuration of the available spica table.

One member of the surgical team should be dedicated to holding the leg in the planned casting position of 45° of hip flexion and 45° of knee flexion with slight abduction (30-45°) and longitudinal traction. The well leg should be flexed and abducted as well to prevent pelvic tilt. Web roll cast padding is circumferentially rolled around the injured leg from just proximal to the malleoli to the xiphoid process with careful attention to padding bony prominences. The foot and ankle are left completely free. Longitudinal strips of 2-inch cast padding are applied anterior to posterior to provide additional padding in the groin and perineal region.

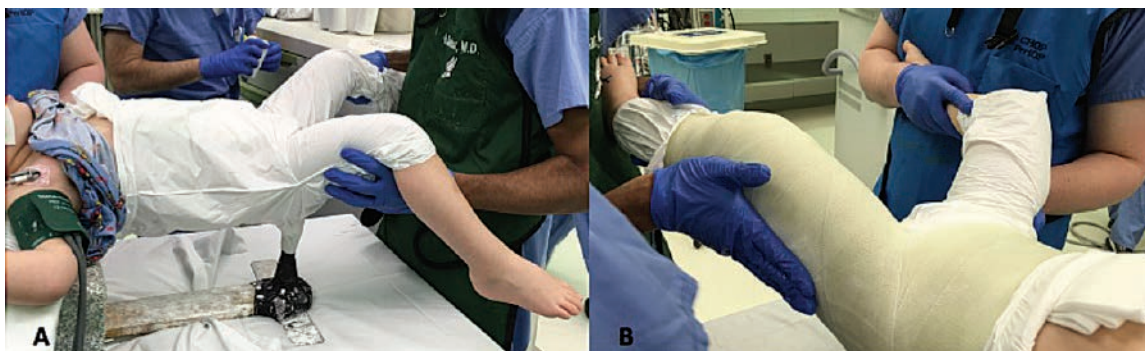
Fiberglass casting material is applied first proximal to distal to create a long leg cast and a valgus mold is applied at the fracture site to prevent varus malalignment (Figure 2). Bi-planar fluoroscopy is used to confirm appropriate length, alignment, rotation and cast molding. Up to 2 cm of shortening, 10 degrees of Varus, and 20 degrees of sagittal displacement are acceptable criteria for reduction. Fiberglass is subsequently applied to reinforce the connection between leg and pelvis. A figure of 8 pattern is useful when circumnavigating the pelvis. Fiberglass struts consisting of 6-8 layers of casting tape are added to provide additional mechanical integrity between the trunk and leg along the anterior thigh, lateral thigh, and medial groin (Figure 3).

The liner is folded back and a final layer of fiberglass is applied. The child should be removed from the casting table

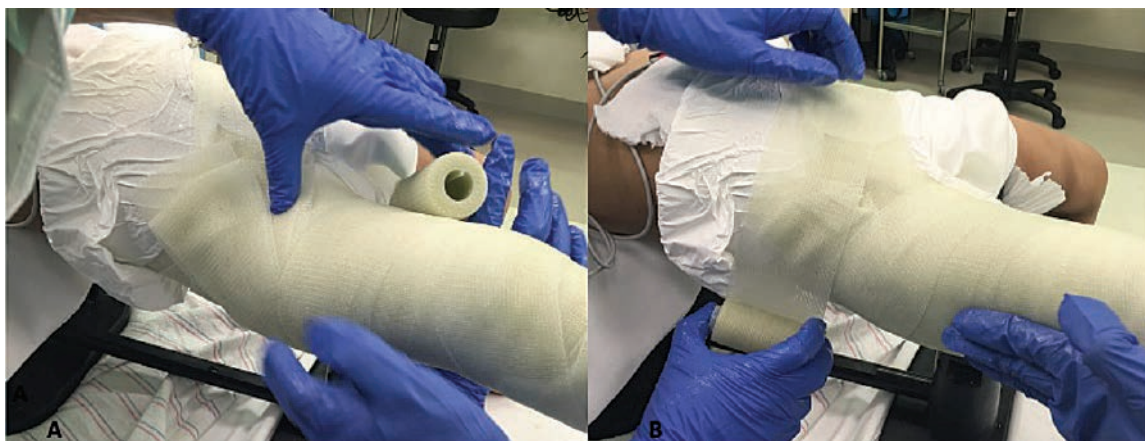and rotated into the lateral position so that all portions of the cast can be inspected for sharp edges that may need to be trimmed. Fluoroscopy is used to confirm acceptable reduction and a radiopaque object should be used to annotate the cast at the fracture location in the event that cast wedging is needed at follow up (Figure 4). The stockinette or towels are removed from the abdomen and two diapers (one small to be placed under the cast edges and one larger overtop) are applied to prevent cast soiling.

### Postoperative Protocol

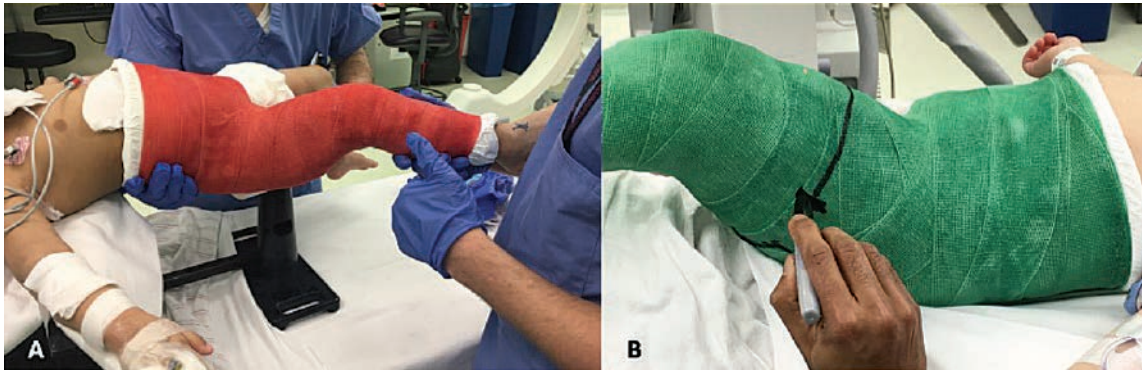
Perioperative management includes pain management, cast care instruction by trained staff, and physical therapy evaluation to ensure safe transport. Follow-up examinations with x-rays are performed at one, two, three, and six weeks post-operatively. Young children will self-restrict weight bearing as comfort allows, with formal clearance for weight bearing when callus is visualized on radiographs. Cast wedging can be performed for coronal or sagittal displacement, typically within the first two weeks following reduction. Loss of reduction may require repeat closed reduction or surgical intervention. Casts are removed after clinical and radiographic evidence of union. Reluctance to walk is common following cast removal and limping may persist for up to a year<sup>7</sup>. Physical therapy is generally not indicated. Additional follow up visits are scheduled for 3 and 12 months post operatively, with subsequent visits on an as needed basis.



**Figure 2.** (A) Once the liner is in place the child is lifted onto the spica table and soft roll applied (B) Initial layer of cast tape is placed and a valgus mold applied.



**Figure 3.** (A) 6-8 layer fiberglass struts are added to enhance the mechanical stability between the leg and pelvis portion of the cast and (B) overlapped with one layer of casting tape.



**Figure 4.** (A) Final casting position. The child can now be removed from the spica table and final fluoroscopy taken (B) The cast can be annotated using fluoroscopy to facilitate future wedging.

## Discussion

Single leg spica casting provides an attractive alternative to the traditional one and a half leg spica cast when used appropriately. This technique can be used safely in children aged 6 months to 4 years with low energy fractures to obtain satisfactory outcomes while minimizing the treatment burden on the patient and family.

## References

1. Kocher MS, Sink EL, Blasler RD, Luhmann SJ, Mehlman CT, Scher DM, *et al*. Treatment of pediatric diaphyseal femur fractures. *J Am Acad Orthop Surg*. 2009;17(11):718-25.
2. Epps HR, Molenaar E, O'Connor D P. Immediate single-leg spica cast for pediatric femoral diaphysis fractures. *J Pediatr Orthop*. 2006;26(4):491-6.
3. Flynn JM, Garner MR, Jones KJ, D'Italia J, Davidson RS, Ganley TJ, *et al*. The treatment of low-energy femoral shaft fractures: a prospective study comparing the "walking spica" with the traditional spica cast. *J Bone Joint Surg Am*. 2011;93(23):2196-202.
4. Hughes BF, Sponseller PD, Thompson JD. Pediatric femur fractures: effects of spica cast treatment on family and community. *J Pediatr Orthop*. 1995;15(4):457-60.
5. Leu D, Sargent MC, Ain MC, Leet AI, Tis JE, Sponseller PD. Spica casting for pediatric femoral fractures: a prospective, randomized controlled study of single-leg versus double-leg spica casts. *J Bone Joint Surg Am*. 2012;94(14):1259-64.
6. Mansour AA, 3rd, Wilmoth JC, Mansour AS, Lovejoy SA, Mencia GA, Martus JE. Immediate spica casting of pediatric femoral fractures in the operating room versus the emergency department: comparison of reduction, complications, and hospital charges. *J Pediatr Orthop*. 2010;30(8):813-7.
7. Flynn JM, Schwend RM. Management of pediatric femoral shaft fractures. *J Am Acad Orthop Surg*. 2004;12(5):347-59.