



Biceps Tenotomy in the Presence of a Supraspinatus Tear Alters the Adjacent Intact Tendons and Glenoid Cartilage

Zakary Beach, BS
Jennica Tucker, BS
Stephen Thomas, PhD
Katherine Reuther, PhD
Chancellor Gray, MD
Chang-Soo Lee, MD
David Glaser, MD
Louis Soslowsky, PhD

McKay Orthopaedic Research Laboratory,
University of Pennsylvania, Philadelphia, PA

Introduction

A rotator cuff tear is a common injury in athletes and workers who repeatedly perform overhead movements, and it is not uncommon for this demographic to return to activity shortly after treatment. A biceps tenotomy can be performed in the presence of a rotator cuff tear to reduce pain and improve joint function¹. However, the effect of this procedure on the surrounding tissues in the glenohumeral joint is unknown. Therefore, the purpose of this study was to investigate the effects of a biceps tenotomy in the presence of a supraspinatus rotator cuff tear, followed by overuse activity as well as the mechanical and histologic properties of the remaining rotator cuff tendons and glenohumeral articular cartilage. We hypothesized that a biceps tenotomy in this context would result in adverse changes in the surrounding tissues demonstrated by a decrease in joint function, as well as decreased mechanics and increased cellular activity in the intact tendons and glenoid cartilage.

Materials and Methods

Experimental Design

46 adult male Sprague-Dawley rats underwent 4 weeks of overuse activity (downhill (10°) treadmill running at 17 m/min for 1h/day, 5 days/week)² to create a tendinopathic condition in the supraspinatus tendon. Next, the animals were randomized into two groups: unilateral detachment of the supraspinatus tendon alone (SO) or detachment of the supraspinatus and long head of the biceps tendons (SB), as previously described³. After surgery, animals were allowed 1 week of cage activity before returning to the overuse training over 2 weeks. After training, all animals underwent 5 weeks of overuse activity⁴.

Ambulatory Measurement

Forelimb gait and ground reaction forces were quantified using an instrumented walkway⁴. Data was collected 1 day prior to tendon detachment to obtain baseline values and also at 3, 7, 14, 28, 42 and 56 days post-surgery.

Tendon Mechanical Testing

Tendon testing was performed as previously described³. Briefly, stain lines were used to track

optical strain. Cross-sectional area was measured using a custom laser device⁵. Tensile testing was performed as follows: preload to 0.08 N, preconditioning (10 cycles of 0.1-0.5 N at a rate of 1% strain/s), stress relaxation to 5% strain at a rate of 5% strain for 600 seconds, then ramp to failure at 0.3% strain/s.

Cartilage Mechanical Testing

For cartilage thickness measurements⁴, specimens were scanned using ultrasound. Each thickness map was divided into six regions, and a mean thickness was computed for each region. Utilizing a 0.5-mm-diameter, nonporous spherical indenter, cartilage indentation testing was performed⁴. Briefly, a preload (0.005 N) was followed by eight stepwise stress relaxation tests (8 μ m ramp at 2 μ m/second followed by a 300 second hold). Equilibrium elastic modulus was calculated, as described⁶, at 20% indentation thickness and assuming Poisson's ratio ($\nu = 0.30$).

Histology

Tendon samples were stained with hematoxylin and eosin, while cartilage samples were stained with safranin O, fast green and iron hematoxylin. Tendon sections were graded for cellularity and cell shape⁴. Cartilage sections were graded using a modified Mankin Score⁷.

Statistical Design

For ambulation data, significance was assessed using a two-way ANOVA, followed by paired t-tests when appropriate. Multiple imputations for missing data (~15%) were conducted on the ambulatory measures. Tendon and cartilage mechanics were evaluated using t-tests. For histology, median grades were compared between groups using a Mann-Whitney test. Significance was set at $p < 0.05$.

Results

Biceps tenotomy resulted in no differences in ambulatory measurements. The lower subscapularis tendon did not show any midsubstance changes or in its insertion between groups. However, the upper subscapularis tendon increased its insertion area in the presence of the detachment of the long head of the biceps (Figure 1A). Increases in the moduli of infraspinatus and upper subscapularis

tendons (Figure 1B) were also found. An increase in tendon midsubstance elastic modulus was also seen in the upper subscapularis tendon (Figure 2). Biceps tenotomy did not reveal changes in elastic modulus in the insertion of the infraspinatus, lower subscapularis or upper subscapularis tendons. Histology showed a significantly increased score for cell shape in the midsubstance of the infraspinatus tendon, signifying that the cells present may be more metabolically active. Results showed no differences in the lower or upper subscapularis tendons in cellularity or cell shape in any region. The biceps tenotomy group showed a significant decrease in glenoid articular cartilage thickness in the anterior-superior region and a significant increase in the superior region when compared to the intact long head of biceps tendon group (Figure 3A). The biceps tenotomy group also showed significantly greater equilibrium elastic modulus in the center and anterior-superior regions (Figure 3B). Histology showed significant increases in modified Mankin score in the biceps tenotomy group in the center, anterior-superior and posterior-superior regions of the glenoid articular cartilage.

Discussion

Results suggest that the tissues in the surrounding joint are altered when a biceps tenotomy is performed in the presence of a supraspinatus only rotator cuff tear. The alterations seen in the infraspinatus and upper subscapularis tendons in the presence of a biceps tenotomy could be caused by an interruption in the anterior-posterior force balance, which

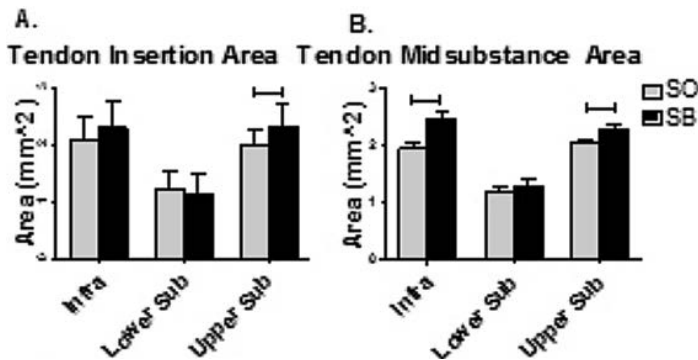


Figure 1. (A) Infra and upper subscap tendon midsubstance area was increased in SB group. (B) Upper subscap tendon insertion area was increased in SB group.

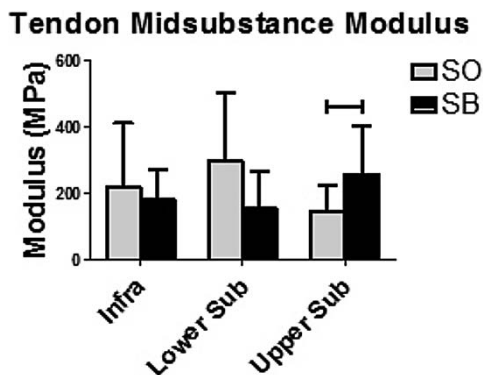


Figure 2. Upper subscap tendon midsubstance elastic modulus was increased in SB group.

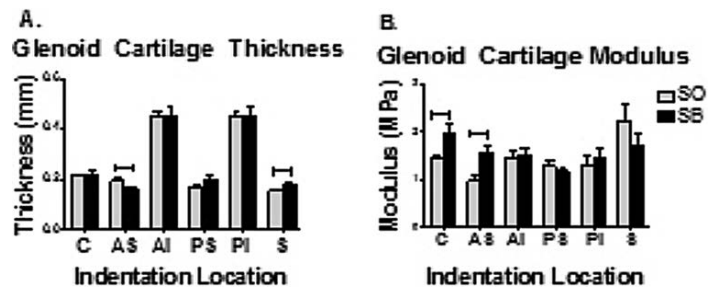


Figure 3. (A) Glenoid cartilage thickness was altered in the anterior-superior and superior regions. (B) Glenoid cartilage modulus was increased in the center and anterior-superior regions.

has been shown to be important to joint health and function⁸. The altered mechanical properties of the glenoid articular cartilage, combined with the increased modified Mankin score, suggests that a biceps tenotomy in the presence of a supraspinatus tendon tear alters the loading in the superior half of the glenoid articular cartilage, which could be due to increased humeral head translation in the absence of the long head of the biceps tendon⁹. These findings show that the biceps tenotomy exacerbates the negative effects associated with overuse after a supraspinatus only tear⁴. Results indicate that the properties of the surrounding tendons and glenoid cartilage are altered in the presence of the biceps tenotomy, perhaps due to decreased joint stability. Future studies are needed concerning biceps tenotomy in the presence of a rotator cuff tear in humans to determine whether the short-term pain-relief of the biceps tenotomy results in increased joint damage long-term.

Conclusions

This work demonstrates that a biceps tenotomy in the presence of a supraspinatus tendon rotator cuff tear affects the surrounding tissues in the rotator cuff of a rat model. Therefore, alternative methods of treatment should be explored that aim to address patient-specific problems while preserving long-term joint health.

Acknowledgements

This study was funded by the NIH/NIAMS (R01 AR056658) and the Penn Center for Musculoskeletal Disorders (P30 AR056658). The authors thank Daniel Choi, James Cirone, Brianne Connizzo, George Fryhofer and Nabeel Salka for their contributions.

References

1. Szabó I, Boileau P, Walch G. The proximal biceps as a pain generator and results of tenotomy. *Sports Med Arthrosc.* 2008 Sep;16(3):180-6. doi: 10.1097/JSA.0b013e3181824f1e. Review. PubMed PMID: 18703979.
2. Soslowky LJ, Thomopoulos S, Tun S, Flanagan CL, Keefer CC, Mastaw J, Carpenter JE. Neer Award 1999. Overuse activity injures the supraspinatus tendon in an animal model: a histologic and biomechanical study. *J Shoulder Elbow Surg.* 2000 Mar-Apr;9(2):79-84. PubMed PMID: 10810684.
3. Peltz CD, Perry SM, Getz CL, Soslowky LJ. Mechanical properties of the long-head of the biceps tendon are altered in the presence of rotator cuff tears in a rat model. *J Orthop Res.*

2009 Mar;27(3):416-20. doi: 10.1002/jor.20770. PubMed PMID: 18924143; PubMed Central PMCID: PMC2819372.

4. Reuther KE, Sarver JJ, Schultz SM, Lee CS, Sehgal CM, Glaser DL, Soslowsky LJ. Glenoid cartilage mechanical properties decrease after rotator cuff tears in a rat model. *J Orthop Res.* 2012 Sep;30(9):1435-9. doi: 10.1002/jor.22100. Epub 2012 Mar 9. PubMed PMID: 22407524; PubMed Central PMCID: PMC3374903.

5. Favata M., PhD Thesis, University of Pennsylvania, 2006.

6. Hayes WC, Keer LM, Herrmann G, Mockros LF. A mathematical analysis for indentation tests of articular cartilage. *J Biomech.* 1972 Sep;5(5):541-51. PubMed PMID: 4667277.

7. Salo PT, Hogervorst T, Seerattan RA, Rucker D, Bray RC. Selective joint denervation promotes knee osteoarthritis in the aging rat. *J Orthop Res.* 2002 Nov;20(6):1256-64. PubMed PMID: 12472238.

8. Thomas SJ, Reuther KE, Tucker JJ, Sarver JJ, Yannascoli SM, Caro AC, Voleti PB, Rooney SI, Glaser DL, Soslowsky LJ. Biceps detachment decreases joint damage in a rotator cuff tear rat model. *Clin Orthop Relat Res.* 2014 Aug;472(8):2404-12. doi: 10.1007/s11999-013-3422-8. Erratum in: *Clin Orthop Relat Res.* 2015 Oct;473(10):3321-2. PubMed PMID: 24326594; PubMed Central PMCID: PMC4079864.

9. Alexander S, Southgate DF, Bull AM, Wallace AL. The role of negative intraarticular pressure and the long head of biceps tendon on passive stability of the glenohumeral joint. *J Shoulder Elbow Surg.* 2013 Jan;22(1):94-101. doi: 10.1016/j.jse.2012.01.007. Epub 2012 Apr 18. PubMed PMID: 22516568.